

*What is your Diagnosis?*

## **FOCAL PRURITUS AND ALOPECIA IN LUMBAR AREA IN GUINEA PIGS**

VUČIĆEVIĆ Miloš<sup>1\*</sup>, DOŠENOVIĆ Milan<sup>1</sup>, MITROVIĆ Marko<sup>2</sup>, SIMOVIĆ Nikola<sup>1</sup>, MILČIĆ MATIĆ Natalija<sup>1</sup>, ANIČIĆ Milan<sup>3</sup>

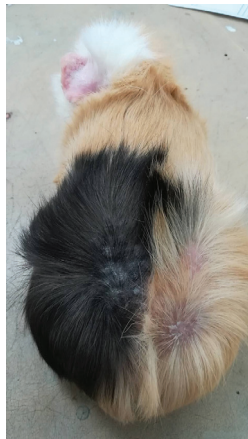<sup>1</sup>University of Belgrade, Faculty of Veterinary Medicine, Department of Equine, Small Animal, Poultry and Wild Animal Diseases, Belgrade, Serbia; <sup>2</sup>University of Belgrade, Faculty of Veterinary Medicine, Department of Radiology and Radiation Hygiene, Belgrade, Serbia; <sup>3</sup>University of Belgrade, Faculty of Veterinary Medicine, Department of Pathology, Belgrade, Serbia

Received 3 May 2018; Accepted 24 January 2019

Published online: 5 February 2019

Copyright © 2019 Vučićević et al. This is an open-access article distributed under the Creative Commons Attribution License, which permits unrestricted use, distribution, and reproduction in any medium, provided the original work is properly cited.

### **STUDY TOPIC**



**Figure 1. The patient at admission**

---

\*Corresponding author – e-mail: [vucicevic@vet.bg.ac.rs](mailto:vucicevic@vet.bg.ac.rs)

## CASE PRESENTATION

### History

From June to December 2017, four male guinea pigs (3-4 years old) with different owners were brought to the Clinic for Small Animals at the Faculty of Veterinary Medicine, University of Belgrade. All of them presented with an identical symptom – severe pruritus on the dorsal rump. The animals were scratching so intensely that they appeared to be having a seizure. Also, all owners noticed that their animals had become aggressive since the onset of symptoms. One of the animals had self-mutilation trauma. One of the guinea pigs also had a hairless area behind its ears. Also, one animal lived in a pair with another guinea pig that did not have any skin changes.

### Physical examination

Physical examination revealed normal body condition, symmetrical alopecia in the dorsolumbar area, and also in that area, the skin was erythematous and edematous. In the case with animal with self-mutilation trauma lesions, white-yellow crusty areas with inflammation and erosion was observed. Elevated skin temperature in the hairless area was detected using a Thermal camera: Testo 875-1 (Testo Ltd., UK), indicating a local inflammatory process. Palpation in the affected area caused pain in all animals, and they all reacted vigorously. Ultrasound examination did not show any structural changes in organs in the abdominal cavity.

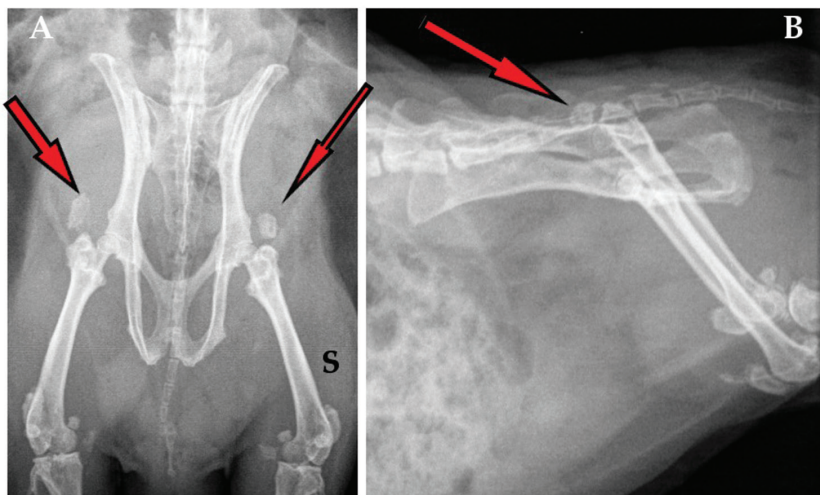


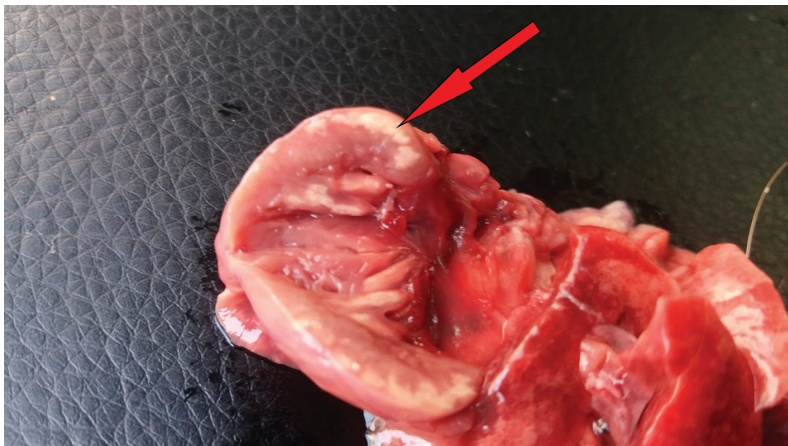Figure 2. Radiography finding: ventrodorsal (A) and lateral (B) views of the pelvis

Due to the pronounced pruritus, we first opted for dermatological examination of the skin. The dermatological examination included skin scraping of the alopecic areas and

cytological examination of the eroded skin. These tests did not show the presence of any parasitic elements or microorganisms that could provoke scratching.

Consequently, radiography was conducted in all four cases, and in each of them, a massive hyperdense area of intensity near bone structures of muscles in the craniodorsal part of both coxofemoral joints was found (Figure 2). The positions of stifle joints were not good for radiological examination, but the shape and structure of visible bones were clear and without the chronic degenerative disease.

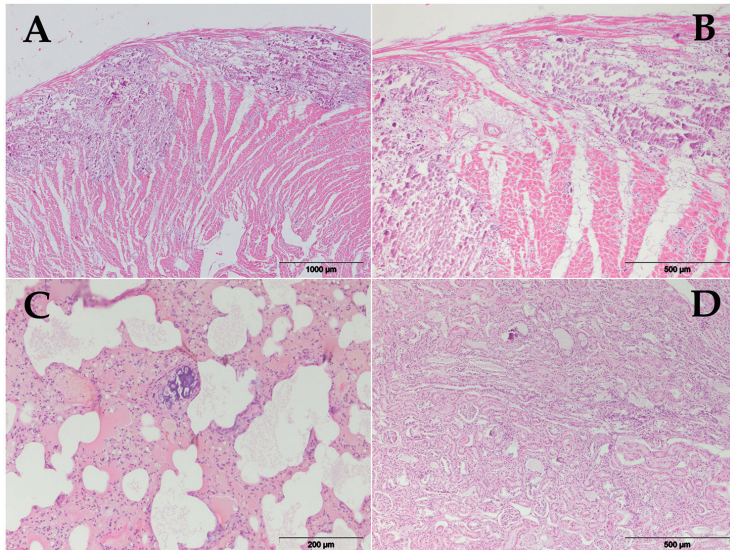
One of the guinea pigs was in a very bad condition and died just after radiological examination. Gross examination did not reveal any skin lesions. Random, multifocal to coalescing, well-demarcated, irregular, pale areas in the myocardium were observed at necropsy (Figure 3). Mild to moderate multifocal mineralization was also evident in the kidney and lung tissue. There was no sign of mineralization in the liver. Histopathological findings included severe, extensive multifocal cardiomyocyte mineralization with degeneration and necrosis, and fibrous tissue proliferation. These lesions were consistent with metastatic mineralization (Figure 4).



**Figure 3. Multifocal cardiomyocyte mineralization**

### **What is your diagnosis?**

- What are your differential diagnoses for pruritus, alopecia and lumbar area pain in guinea pigs with negative parasitological examination?
- What are your differential diagnoses based on radiological examination?
- What could cause the changes observed during the gross and histopathological examinations?



**Figure 4. Histopathology findings: A – Heart (HE, 40x), B – Heart (HE, 100x), C – Lungs (HE, 200x), D – Kidney (HE, 100x)**

## INTERPRETATION

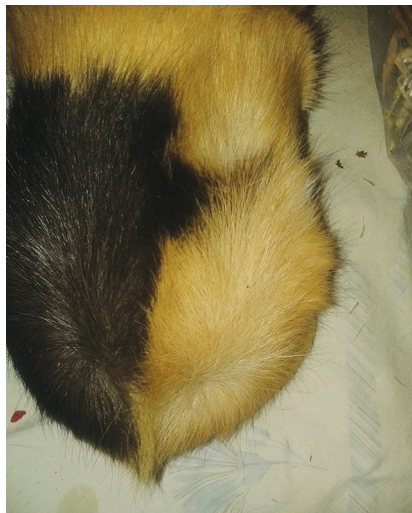The most frequent causes of intense scratching in guinea pigs are parasitic infections. Since dermatological examination did not show the presence of parasites, we took into consideration other conditions that can lead to the onset of these symptoms. This is supported by the fact that the guinea pig that lived in a pair with one of the diseased guinea pigs did not have any skin changes, which is almost impossible for parasitosis.

The differential diagnoses for this condition also include dietary factors such as low-magnesium (Mg) and high-phosphorus (P) diet and high calcium (Ca) and/or high vitamin D intake, inadvertent cholecalciferol rodenticide poisoning, and renal disease.

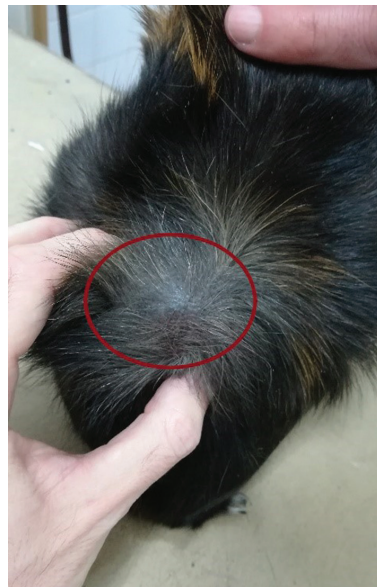Radiological findings indicated the presence of calcification in muscle tissue, and with a negative parasitological examination, we suspected that in all four cases, the condition in question was metastatic calcification.

Three out of four individuals were treated identically – enrofloxacin (Baytril, Bayer Animal Health, Germany) 10 mg kg<sup>-1</sup> was administered for 7 days and ranitidine (Ranitidin, Hemofarm, Serbia) 2 mg kg<sup>-1</sup> and meloxicam (Movalis, Boehringer Ingelheim, Germany) 0.5 mg kg<sup>-1</sup> were administered orally during four weeks. The therapy gave good results in all cases, and animals immediately stopped scratching the affected area. Hair began to grow again, and after one month, the initial changes could not be seen (Figure 5).





**Figure 5. Guinea pig after a one-month-therapy**



**Figure 6. The mass on the dorsal rump**

However, in one guinea pig, we did not succeed in using medication therapy to achieve the desired effect. Five months after the therapy and re-growth of hair on the dorsal rump, a mass the size of 3 times 5 centimetres appeared (Figure 6). A solitary cutaneous nodule on the dorsum of the animal was clinically examined and aspiration by fine needle biopsy was performed. Cytological examination revealed cohesive groups of anucleate, mature, squamous epithelial cells with clear evidence of keratinization. Based on the localization and cytological features of the lesion, it was supposed that the most probable diagnosis is trichofolliculoma.

## **DISCUSSION**

Soft tissue calcification, or metastatic calcification, has been documented in guinea pigs since the middle of the 20<sup>th</sup> century (O'Dell et al., 1957), and is still reported as a disorder that primarily affects males older than one year.

Due to tissue destruction caused by the presence of calcium in lumbar muscles, a pain in that area can be present. Also, pain can be present due to an inflammatory process, which is the result of hydroxyapatite crystals rupturing (Yıldırım et al., 2018). Tsukamoto et al. (2018) explained that the presence of ectopic calcification in soft tissues can be the cause of focal pain which can even be severe. As a consequence of pain, animals start scratching affected areas, causing local skin lesions.

Based on product declaration, properly formulated feed almost always meets the nutritional requirements for Ca and P and has additional vitamin D content.

Unfortunately, guinea pig owners frequently do not adhere to such nutrition, but rather they introduce nutrients that lead to the imbalance of calcium and phosphorus. In our four cases, the nutrition of patients was based on the following plants: cucumber (without skin), celeriac (root and leaf), parsley (root and leaf), pepper (red, green and bell), kohlrabi (root and leaf), carrot, apple, spinach, lettuce, cabbage and dandelion. While the properly formulated feed has not caused any toxicity, the extremely high vitamin D level in the misformulated feed caused tissue mineralization in vital visceral organs and muscles (Villano et al., 2015). The owners of the threatened guinea pigs were advised to feed their pets only with commercially produced guinea pig feed in order to inhibit further changes from occurring.

It is important to emphasize the importance of blood sampling; however, it is not necessary to have increased blood Ca values to produce tissue calcification (Camberos et al., 1970; Villano et al., 2015).

Based on the fact that guinea pigs are extremely sensitive to stress, the diagnostic method of choice in this case is certainly X-ray radiography. To the best of our current knowledge, it is impossible to mitigate the condition when changes occur, since the process is irreversible. Affected guinea pigs should be treated with nonsteroidal analgesics to remove pain in order to allow individuals to manifest physiological forms of behavior and prevent further self-mutilation.

## REFERENCES

- Camberos H.R., Davis G.K., Djafar M.I., Simpson C.F. 1970. Soft tissue calcification in guinea pigs fed the poisonous plant *Solanum malacoxylon*. *Am J Vet Res*, 31: 685-696.
- O'Dell B.L., Morris E.R., Pickett E.E., Hogan A.G. 1957. Diet composition and mineral balance in guinea pigs. *J Nutr*, 63: 65-77, DOI: 10.1093/jn/63.1.65
- Villano J.S., Fann M.K., Suckow C.E., Cooper T.K. 2015. Diagnostic exercise: Metastatic calcification in guinea pigs. *Veterinary Pathology*, 52: 757-759, DOI: 10.1177/0300985814552107
- Tsukamoto Y, Futani H, Watanabe T, Kemmoku K, Iwayama T, Matsuo S, Hirota S, Yoshiy S. 2018. Two cases of WWTR1-CAMTA-1 fusion-positive epithelioid hemangioendotheliomas with extremely different outcomes. *Human Pathology: Case Reports*, 14: 25-32, <https://doi.org/10.1016/j.chpc.2018.07.003>
- Yıldırım M.A., Gökşenoğlu G, Ganiyusufoglu A.K., Paker N., Öneş K. 2018. Calcific tendinitis of longus colli muscle. *Pam Med J*, 11(2):165-167, doi: 10.5505/ptd.2018.87059

## **FOKALNI PRURITUS I ALOPECIJA U LUMBALNOM PODRUČJU ZAMORACA**

VUČIĆEVIĆ Miloš, DOŠENOVIĆ Milan, MITROVIĆ Marko,  
SIMOVIĆ Nikola, MILČIĆ MATIĆ Natalija, ANIČIĆ Milan

### **Kratak sadržaj**

Četiri odrasla morska praseta muškog pola sa izraženim svrabom u kaudalnom delu leđa su primljena na pregled. Ustanovljeno je prisustvo lokalnog, bolnog, pruritičnog edema. Parazitološki nalaz je bio negativan. Radiografija je pokazala prisustvo kalcifikacija u predelu kokso-femoralnog zgloba. Ovo nas je navelo da posumnjamo na metastatsku kalcifikaciju. Životinje su tretirane meloksikamom 0,5 mg/kg nakon čega je došlo do znatnog poboljšanja stanja. Nakon smrti jedne jedinke, obdukcija je otkrila kalcifikacije na mišićima, u srcu, bubrezima i plućima.