

FEASIBILITY AND ECHOCARDIOGRAPHIC CHARACTERISTICS OF A THREE-MINUTE STAGE DOBUTAMINE STRESS TEST IN HEALTHY DOGS

SPASOJEVIĆ KOSIĆ Ljubica^{1*}, TRAILOVIĆ R. Dragiša²

¹University of Novi Sad, Faculty of Agriculture, Department of Veterinary Medicine, Novi Sad, Serbia;

²University of Belgrade, Department of Equine, Small Animal, Poultry and Wild Animal Diseases, Belgrade, Serbia

Received 24 March 2018; Accepted 07 September 2018

Published online: 24 October 2018

Copyright© 2018 Spasojević Kosić and Trailović. This is an open-access article distributed under the Creative Commons Attribution License, which permits unrestricted use, distribution, and reproduction in any medium, provided the original work is properly cited

Abstract

Introduction. Dobutamine stress test (DST) is used as a method of functional cardiac examination in human medicine due to dobutamine's effect, which is similar to moderate physical exercise. The aim of this study was to assess the feasibility and echocardiographic characteristics of a conventional DST in dogs.

Materials and Methods. Ten clinically healthy German Shepherd dogs were submitted to a conventional 3-minute stage DST protocol (the initial dose 7.5 µg/kg/min was increased at 3-minute intervals by 5 µg/kg/min until a maximum dosage of 42.5 µg/kg/min; the maximum DST duration was 24 minutes), which is used in human medicine. Dobutamine action was monitored by noninvasive diagnostic methods (simultaneously lead II electrocardiography and transthoracic echocardiography). Left ventricular echocardiographic parameters were measured at baseline and at the peak of DST.

Results and Conclusions. The duration of conventional DST in dogs was 19.4±4.06 minutes. During the DST, sinus tachycardia was registered with no abnormalities of cardiac rhythm. The adverse effects registered in this study were excitement, panting and weakness. Interventricular septum thickness in systole ($P=0.0093$) and diastole ($P=0.0080$) increased significantly at the peak of DST. The left ventricular end-systolic dimension ($P=0.0077$) and the diastolic wall stress index ($P=0.0125$) decreased significantly at the peak of DST. A 3-minute stage with increased doses of dobutamine is a feasible method for the DST in dogs. The registered changes could be explained by the dobutamine effects through β_1 adrenergic receptors. This pharmacological stress test induces significant changes in left ventricular echocardiographic parameters in healthy adult dogs. Dogs exhibit transient signs like sinus tachycardia, excitement,

*Corresponding author – e-mail: ljubicask@polj.uns.ac.rs

panting and weakness during DST. Additional research on DST should evaluate the diagnostic value of this protocol in dogs suffering from cardiac disease.

Key Words: dobutamine, dog, echocardiography, pharmacological stress test

INTRODUCTION

Dobutamine stress echocardiography (DSE) is accepted in human medicine as a noninvasive method for coronary artery disease diagnosis and risk stratification, detection of myocardial ischemia and valvular dysfunction, evaluation of cardiac versus noncardiac origin of chest pain or dyspnea, as well as preoperative risk assessment. Contraindications for DSE in humans include conditions like acute myocardial infarction, acute pericarditis or myocarditis, symptomatic and severe aortic stenosis, stenotic valvular heart disease, main coronary artery stenosis, acute aortic dissection, uncontrolled and hemodynamically relevant arrhythmias, decompensated heart failure, pulmonary embolism, severe hypertension and severe electrolyte abnormalities. Conventional DSE protocols require graded infusions of dobutamine using an escalating dose at 3-minute intervals, starting at a dose of 5 or 10 $\mu\text{g}/\text{kg}/\text{min}$ and increasing by 10 $\mu\text{g}/\text{kg}/\text{min}$ to a final dose of 40 $\mu\text{g}/\text{kg}/\text{min}$. However, no standardized dobutamine stress test (DST) exists in human medicine, and safety, feasibility and diagnostic accuracy of different protocols were reported. These protocols vary from 3-minute to 5-minute stage duration (Katritsis et al., 2005; Kamaran et al., 1995) and from a low dose (5 or 10 $\mu\text{g}/\text{kg}/\text{min}$) (Schinkel et al., 2004) to a high dose (20 and/or 40 $\mu\text{g}/\text{kg}/\text{min}$) dobutamine infusion (San Roman et al., 2003; Lu et al., 2001).

In canine cardiology, the pharmacological stress test is still in the investigational phase. Although DST has been already described in dogs by other authors (Suzuki et al., 2014; Spasojevic Kotic et al., 2012; Sousa et al., 2005, 2004; McEntee et al., 2001, 2000, 1998, 1996; Minors & O'Grady, 1998), the indications for DST in canine medicine are not well defined. Indications of DSE in dogs could include an assessment of cardiac functional capacity in patients where conventional and advanced echocardiographic analysis of ventricular systolic function gave ambiguous results. To date, reported DST protocols in conscious dogs utilized low constant dose of dobutamine infusion (5 $\mu\text{g}/\text{kg}/\text{min}$) (Minors & O'Grady, 1998), as well as incremental dobutamine infusion (Spasojevic Kotic et al., 2012; Sousa et al., 2005, 2004; McEntee et al., 2001, 1998, 1996). There is no data available on the subject of comparing different DST protocols in conscious dogs, neither healthy dogs nor dogs with cardiac diseases.

In order to expand our knowledge of DST in dogs, the conventional DST protocol used in human medicine was performed in this study. We wanted to explore whether or not this test is suitable for clinical examination and whether it had a similar echocardiographic profile as other reported DST protocols in dogs. Previous studies have investigated echocardiographic factors (Sousa et al., 2004; McEntee et al., 2001, 1998; Minors & O'Grady, 1998) and hormonal response (Spasojevic Kotic et al.,

2012; McEntee et al., 2000) associated with DST. In this paper, the effect of the conventional DST on left ventricular echocardiographic parameters is presented as echocardiographic values obtained before and at the DST peak in order to compare its effects with the echocardiographic parameters values observed by other authors with different DST protocols.

MATERIALS AND METHODS

Animals

Ten German Shepherd dogs owned by colleagues (8 males and 2 females, 1 to 9 years old, body weight 26 ± 4.57 kg) were studied. The dogs were considered healthy based on the history, physical examination, complete blood count and serum chemistry, as well as conventional six-lead electrocardiography (ECG), and two-dimensional (2D) and M-mode echocardiography. All examinations were performed on conscious dogs using manual restraint. The experimental protocol was approved by the Ethical Committee of the Faculty of Veterinary Medicine, University of Belgrade.

Dobutamine stress test

The DST was performed by administering dobutamine (Dobutamine, Panpharma S.A., Le Clairay, France) via the cephalic vein. The initial dose of $7.5 \mu\text{g}/\text{kg}/\text{min}$ was increased at 3-minute intervals, by $5 \mu\text{g}/\text{kg}/\text{min}$, until a maximum dosage of $42.5 \mu\text{g}/\text{kg}/\text{min}$ was achieved. The criterion of maximum response to DST (DST peak) was fulfilled when the dog received the maximum dosage of DST ($42.5 \mu\text{g}/\text{kg}/\text{min}$) or when one of the following signs was detected: sinus tachycardia over 200/min, severe arrhythmia (paroxysmal ventricular tachycardia) or uncontrollable excitement of the animal (McEntee et al., 1996).

Echocardiographic examinations (300S Pandion Vet, Esaote Pie Medical, Maastricht, the Netherlands) were performed in 2D and M modes using a 5 MHz probe by an experienced veterinary internist with particular interest in cardiology. DSE was performed on the dogs in the standing position. Echocardiographic measurements were done from the right parasternal location by using two-dimensional guided M-mode echocardiograms. The M-mode cursor line was placed at the left ventricular chamber level, just below the tips of the mitral valve in order to avoid papillary muscles within the left ventricle. Measurements were performed in accordance with the recommendations of the American Society of Echocardiography (Sahn et al., 1978). The mean of three cardiac cycles was taken as the result of measurement. Echocardiographic values (interventricular septal thickness in diastole-IVSd, interventricular septal thickness in systole-IVSs, left ventricular end-diastolic dimension-LVEDD, left ventricular end-systolic dimension-LVESD, left ventricular free wall thickness in diastole-LVFWd, left ventricular free wall thickness in systole-LVFWs) were measured before dobutamine administration and at the moment of

DST peak. During DST, the cardiac echocardiography (2D from right parasternal longitudinal axis) was monitored simultaneously in order to recognize maximum response to DST and to terminate dobutamine infusion. Continuous lead II ECG, which was integrated in the ultrasound machine, was monitored during DST in order to determine the heart rate (HR) and arrhythmia.

The fractional shortening of left ventricle (FS-LV), the left ventricular free wall percent thickening (LVW%T), the systolic wall stress index (WSIS) and the diastolic wall stress index (WSID) were calculated using the following formulas (Minors & O'Grady, 1998):

$$\text{FS-LV (\%)} = \text{LVEDD-LVESD} / \text{LVEDD} \times 100$$

$$\text{LVW\%T} = 100 \times (\text{LVFWs-LVFWd}) / \text{LVFWd}$$

$$\text{WSIS} = \text{LVESD} / \text{LVWs}$$

$$\text{WSID} = \text{LVEDD} / \text{LVWd}$$

Statistical analysis

Data analysis was performed using a commercial software package, Statistica 12. All quantitative variables are reported as the mean \pm standard deviation (SD). A nonparametric Wilcoxon matched pairs test was performed to compare the values of echocardiographic parameters from baseline to peak infusion. A probability value of $P < 0.05$ was considered significant. Qualitative variables were expressed in percentages.

RESULTS

All dogs tolerated the DST well. The average duration of DST was 19.4 ± 4.06 minutes (13-24 minutes). The maximum level of DST in the dogs was determined by monitoring HR, cardiac echo, ECG, and dogs' behavior. In nine dogs, the end point of DST was reached at the $\text{HR} > 200/\text{min}$. In one dog, there was no increase of HR over $200/\text{min}$, despite the fact that this dog received the full dosage range of dobutamine. Target HRs were observed at doses of dobutamine ranging from $27.5\text{-}42.5 \mu\text{g}/\text{kg}/\text{min}$ (mean peak dose 35.5 ± 6.32). Only a sinus tachycardia ($\text{HR} > 200/\text{min}$) was observed; no rhythm disturbances were observed during DST. After the termination of dobutamine application, the HR decreased rapidly to a more physiological range of values ($60\text{-}160/\text{min}$). During DST, excitement, panting and weakness were observed in some dogs (Figure 1). None of these side effects was judged to be severe enough to lead to interruption of the experimental protocol.

The dobutamine challenge resulted in IVSd and IVSs increases, a LVESD decrease, higher FS-LV and lower WSID (Table 1). The values of IVSd ($P=0.0080$) and IVSs ($P=0.0093$) at the peak of DST were significantly higher compared with baseline values. The LVESD at the peak of DST was significantly different ($P=0.0077$) from the LVESD value before DST. The WSID was significantly lower at the peak of DST compared with baseline values ($P=0.0125$).

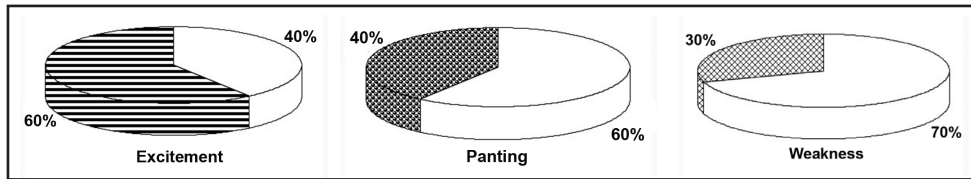


Figure 1. Percentages of noncardiac adverse effects: (A) excitement, (B) panting, (C) weakness in dogs undergoing DST

Table 1. Echocardiographic parameters in dogs before dobutamine infusion and at the moment of DST peak

Parameters	DST before	DST peak	p value
IVSd (cm)	0.72±0.08	0.84±0.09	0.0080
IVSs (cm)	0.92±0.11	1.07±0.08	0.0093
LVEDD (cm)	3.91±0.45	3.72±0.37	NS
LVESD (cm)	2.79±0.18	2.45±0.30	0.0077
LVFWd (cm)	0.79±0.15	0.86±0.10	NS
LVFWs (cm)	1.05±0.18	1.06±0.13	NS
FS-LV (%)	28.25±4.87	34.14±4.37	NS
LVW%T (%)	34.37±14.52	25.03±18.17	NS
WSIS	2.71±0.33	2.33±0.39	NS
WSID	5.05±0.56	4.41±0.83	0.0125

Data are presented as mean±SD. P < 0.05 = significant, NS = nonsignificant.

IVSd – interventricular septal thickness in diastole, IVSs – interventricular septal thickness in systole, LVEDD – left ventricular end – diastolic dimension, LVESD – left ventricular end – systolic dimension, LVFWd – left ventricular wall thickness in diastole, LVFWs – left ventricular wall thickness in systole, FS-LV – fractional shortening of left ventricle, LVW%T – left ventricular free wall percent thickening, WSIS – systolic wall stress index, WSID – diastolic wall stress index.

DISCUSSION

Dobutamine is a potent β_1 adrenergic agonist with minimal β_2 and α adrenergic effects. The primary effect of dobutamine infusion, as a diagnostic tool, constitutes an increase in HR and systolic blood pressure that results in an increase in myocardial oxygen demand, similar to that occurring during moderate physical exercise (Wackers, 1993). DSE is accepted as a noninvasive method with defined indications and contraindications for evaluating the cardiovascular system in humans. In canine cardiology, DST has proved to be a sensitive, noninvasive diagnostic method for detecting early cardiac dysfunction in dogs with asymptomatic dilated cardiomyopathy (McEntee et al., 2001; Minors & O'Grady, 1998). The DST is especially effective in diagnosing systolic dysfunction provoked by doxorubicin (Sousa et al., 2004) or generated by mitral regurgitation (Suzuki et al., 2014).

High doses of dobutamine in a DST induce myocardial ischemia both in humans (Coma-Canella, 1991) and dogs (Spasojevic Kotic et al., 2012), which supports the value of the test. The ability of the DST to detect myocardial ischemia in humans is dependent on an adequate increase in myocardial oxygen consumption, which is directly related to the HR achieved during stress (Tsutsui et al., 2005). The target HR of stress echocardiography in human medicine is 85% of the age and gender maximum predicted HR. Many patients in conventional DSE protocols do not reach the target HR and require atropine, which by removal of parasympathetic tone, further augments the HR response (Mertes et al., 1993). In the studies of McEntee et al. (1998, 1996), target HRs were over 200/min or 240/min and maximum HRs were reached at a dosage ranging from 27.5- 42.5 µg/kg/min. HRs over 200/min were reached with the same doses in our study. Because the direct chronotropic effect of dobutamine is neutralized by the reflex slowing of HR due to baroreceptor reflex action (Liang et al., 1981), after termination of dobutamine application, we observed HR decreases.

Dobutamine pharmacodynamics require approximately 10 minutes to reach a steady state. Despite this, standard DSE in humans typically uses 3-minute stages of advancing dobutamine doses because of safety concerns (Lu et al., 2001). In addition, DSE is considered time consuming and labor intensive, and it has been suggested that an accelerated protocol of DST increases the feasibility and the cost effectiveness of stress echocardiography in human cardiology (SanRoman et al., 2003; Lu et al., 2001). This is even more important for veterinary medicine, because of the uncooperativity of the patients. In the studies of McEntee et al. (McEntee et al., 2001, 1998, 1996), the dogs were trained to lie quietly on a table. The maximum time that dogs spent undergoing the procedure was 75 minutes. This duration of test, under clinical circumstances, is too long for many dogs. In our study, the average duration of DST was 19.4 ± 4.06 minutes, with the maximum DST duration being 24 minutes. Tolerance for this DST protocol was good. Occurrences of adverse effects were lower than previously reported in healthy dogs evaluated with less aggressive DST protocols (Sousa et al., 2005; McEntee et al., 1998, 1996). In many protocols, dobutamine is administered in higher doses than those for therapeutic purposes, potentially increasing the risk of adverse effects and complications. The most common cardiac adverse effects of DST in humans are ischemia and benign arrhythmias (isolated premature atrial or ventricular complexes) (Mertes et al., 1993). In contrast, life-threatening arrhythmias, such as sustained ventricular tachycardia and ventricular fibrillation, are rare complications of DSE (Lima et al., 2008; Katritsis et al., 2005; Mertes et al., 1993). Noncardiac adverse effects of DST in humans are nausea, anxiety, headache, dizziness, tremor, dyspnea and urgency (SanRoman et al., 2003; Lu et al., 2001; Mertes et al., 1993). Adverse effects reported in dogs during dobutamine infusion were arrhythmias (ventricular premature complexes, paroxysmal ventricular tachycardia) (Sousa et al., 2005; McEntee et al., 2000, 1998) panting, vomiting, congested mucous membranes and uncontrollable excitement (McEntee et al., 1998, 1996). In our study, the adverse effects of dobutamine were mostly noncardiac (excitement and panting).

In humans, the DSE is coupled to an accurate analysis of different segments of the left ventricular walls to detect segmental changes of myocardial function as a result of coronary artery disease. Such an echocardiographic approach has not been standardized in canine DST, and our echocardiographic analysis was limited to conventional M-mode analysis of the global left ventricular function. It is expected that dobutamine has an influence on the left ventricular myocardium; however, LVFWd and LVFWs measurements did not show significant differences associated with DST. The lack of statistical significance may reflect higher variability in the LVFW measurements compared to IVS measurements (Table 1). The results of significantly increased IVSd ($P=0.0080$) and IVSs ($P=0.0093$) in our study suggest that dobutamine, at the used dosages, induces a more profound increase in septal myocardial contractility, as demonstrated in horses undergoing dobutamine or dobutamine/atropine stress echocardiography (Sandersen et al., 2006; Frye et al., 2003). A significant reduction of LVESD ($P=0.0077$) after dobutamine infusion was observed, likely as result of the positive inotropic action of this drug. A similar mechanism could also explain the increased FS-LV ($P=0.0593$) observed during DST. Interestingly, similar echocardiographic changes have been previously reported by other authors in dogs undergoing DST (Sousa et al., 2004; McEntee et al., 2001; Minors & O'Grady, 1998). The diastolic wall stress index (WSID) is the echocardiographic parameter of diastolic function. In healthy Dobermans subjected to low dobutamine infusion, the value of WSID decreased (5.2 ± 0.18 vs. 5.1 ± 0.12), while in Dobermans with occult dilated cardiomyopathy, the value of this index increased (5.7 ± 0.29 vs. 5.9 ± 0.31), but the differences between the baseline and dobutamine examinations were not significant (Minors & O'Grady, 1998). In our study, with an aggressive DST protocol, the value of WSID at the peak of DST was significantly lower compared to the baseline value (5.05 ± 0.56 vs. 4.41 ± 0.83 , $P=0.0125$). Since WSID represents a measure of left ventricle preload (Aurigemma & Gaash, 2007), it could be presumed that preload is also reduced. Both the decrease in LVEDD and the increase in LVFWd, although nonsignificant, led to the diminishing of WSID. Studies performed in dogs (McEntee et al., 1998), horses (Gehlen et al., 2006) and humans (Cnota et al., 2003) suggest the results of a DST are related to decreased preload. In contrast to an exercise stress test, the muscular pump function that leads to increased venous return is missing during the DST (Cnota et al., 2003).

Certain limitations of this study should also be addressed. Conventional DSE protocols in humans enable accurate analysis of each myocardial segment. We based our study on the analysis of left ventricular global function in order to compare fundamental echocardiographic parameters changes induced by the conventional DST with the ones previously reported in conscious dogs submitted to different DST protocols. Although our study was performed in dogs of the same breed, we did not consider the influence of body weight, age or gender on echocardiographic parameters. From the aspect of profound and detailed analysis of ventricular function, the echocardiographic analysis of conventional DST that we performed can be considered as a major limitation of this

study. This is because advanced echocardiographic techniques such as tissue Doppler imaging and speckle-tracking echocardiography are superior (Suzuku et al., 2014; Hori et al., 2007). Potential exclusion criteria for DST in humans are certain arrhythmias and severe hypertension. In accordance with this, 24-hour Holter monitoring and oscillometric blood pressure measurement should have been incorporated into the study. The fact that DST was performed in a small number of healthy animals requires additional studies of conventional DST in dogs with known cardiovascular disease. Comparison of different DST protocols in dogs has to be performed in order to provide standardization in cardiac functional assessment.

CONCLUSION

The present study has provided a basis for conventional DST in dogs. The feasibility of the conventional DST protocol used is acceptable primarily because it requires a shorter period of time than some other protocols. In addition, the echocardiographic characteristics of this conventional DST protocol were similar to those obtained in dogs with DST protocols of longer duration. Lastly, the use of 3-minute stages in DST was safe and not associated with serious adverse effects in our population of healthy dogs. However, additional studies are needed in order to prove the safety and diagnostic accuracy of this dynamic test in dogs with cardiac diseases.

Acknowledgements

This study was performed at the Faculty of Veterinary Medicine, University of Belgrade. The authors would like to thank Dr V. Magaš and Dr A. Spasović for their technical assistance.

Authors contributions

Lj. S. K. designed the study, performed all examinations, analyzed the results and wrote the manuscript. D. R. T. also designed the study, supervised the analysis of the results, and contributed to the writing of the manuscript.

Competing interests

The authors declare that they have no competing interests.

REFERENCES

- Aurigemma, G.P., Gaasch, W.H. 2007. Quantitative evaluation of left ventricular structure, wall stress and systolic function. In *The practice of clinical echocardiography*. Ed. Otto, C.M. Saunders Philadelphia, pp. 187.
- Cnota, J.F., Mays, W.A., Knecht, S.K., Kopser, S., Michelfelder, E.C., Knilians, T.K., Claytor, R.P., Kimball, T.R. 2003. Cardiovascular physiology during supine cycle ergometry and dobutamine stress. *Medicine and Science in Sports and Exercise*, 35:1503-1510. DOI: 10.1249/01.MSS.0000084436.15808.52

- Coma-Canella, I. 1991. Changes in plasma potassium during the dobutamine stress test. *International Journal of Cardiology*, 33:55-59. DOI: [https://doi.org/10.1016/0167-5273\(91\)90152-F](https://doi.org/10.1016/0167-5273(91)90152-F)
- Frye, M.A., Bright, J.M., Dargatz, D.A., Fettman, M.J., Frisbie, D.D., Baker, D.C., Traub-Dargatz, J.L. 2003. A comparison of dobutamine infusion to exercise as a cardiac stress test in healthy horses. *Journal of Veterinary Internal Medicine*, 17:58-64. <https://doi.org/10.1111/j.1939-1676.2003.tb01324.x>
- Gehlen, H., Marnette, S., Rohn, K., Stadler, P. 2006. Stress echocardiography in wormblood horses: comparison of dobutamine/atropine with treadmill exercise as cardiac stressors. *Journal of Veterinary Internal Medicine*, 20:562-568. <https://doi.org/10.1111/j.1939-1676.2006.tb02897.x>
- Hori, Y., Sato, S., Hoshi, F., Huguchi, S. 2007. Assessment of longitudinal tissue Doppler imaging of the left ventricular septum and free wall as an indicator of left ventricular systolic function in dogs. *American Journal of Veterinary Research*, 68(10):1051-1057. <https://doi.org/10.2460/ajvr.68.10.1051>
- Kamaran, M., Teague, S.M., Finkelhar, R.S., Dawson, N., Bahler, R.C. 1995. Prognostic value of dobutamine stress echocardiography in patients referred because of suspected coronary artery disease. *American Journal of Cardiology*, 76:887-891. DOI: [https://doi.org/10.1016/S0002-9149\(99\)80255-0](https://doi.org/10.1016/S0002-9149(99)80255-0)
- Katritsis, D.G., Karabinos, I., Papdopoulos, A., Simeonidis, P., Korovesis, S., Giazityoglou, E., Karvouni, E., Voridis, E. 2005. Sustained ventricular tachycardia induced by dobutamine stress echocardiography: a prospective study. *Europace*, 7:433-439. <https://doi.org/10.1016/j.eupc.2005.05.009>
- Liang, C., Yi, J.M., Sherman, L.G., Black, J., Gavras, H., Hood, W.B. 1981. Dobutamine infusion in conscious dogs with and without acute myocardial infarction: Effects on systemic hemodynamics, myocardial blood flow, and infarct size. *Circulation Research*, 49:170-180.
- Lima, R.deS.L., DeLorenzo, A., Issa, A. 2008. Reduced adverse effects with an accelerated dobutamine stress protocol compared with the conventional protocol: a prospective, randomized, myocardial perfusion scintigraphy study. *International Journal of Cardiovascular Imaging*, 24:55-59.
- Lu, D., Greenberg, M., Little, R., Malik, Q., Fernicola, D.J., Weissman, N.J. 2001. Accelerated Dobutamine stress testing: safety and feasibility in patients with known or suspected coronary artery disease. *Clinical Cardiology*, 24:141-145. <https://doi.org/10.1002/clc.4960240208>
- McEntee, K., Amory, H., Pypendop, B., Balligand, M., Clercx, C., Michaux, C., Jacquemot, O., Robert, F., Gerard, P., Pochet, T., Henroteaux, M. 1998. Effects of dobutamine on isovolumic and ejection phase indices of cardiac contractility in conscious healthy dogs. *Research in Veterinary Science*, 64:45-50. [https://doi.org/10.1016/S0034-5288\(98\)90114-X](https://doi.org/10.1016/S0034-5288(98)90114-X)
- McEntee, K., Clercx, C., Flandre, T., Jonville, E., Pynnaert, C., van Benden, R., Ketelslegers, J.M., Michaux, C., Balligand, M., Miserque, N., Henroteaux, M. 2000. Hormonal response to dobutamine cardiac stress testing in a conscious canine model of early left ventricular dysfunction induced by chronic rate overload. *Journal of Veterinary Cardiology*, 2:7-14. [https://doi.org/10.1016/S1760-2734\(06\)70006-6](https://doi.org/10.1016/S1760-2734(06)70006-6)
- McEntee, K., Clercx, C., Pypendop, B., Peeters, D., Balligand, M. 1996. Cardiac performance in conscious healthy dogs during dobutamine infusion. *Research in Veterinary Science*, 61:234-239. [https://doi.org/10.1016/S0034-5288\(96\)90070-3](https://doi.org/10.1016/S0034-5288(96)90070-3)
- McEntee, K., Clercx, C., Soyeur, D., Amory, H., Michaux, C., Flandre, T., Jonville, E., Pynnaert, C., Miserque, N., Henroteaux, M. 2001. Usefulness of dobutamine stress tests

- for detection of cardiac abnormalities in dogs with experimentally induced early left ventricular dysfunction. *American Journal of Veterinary Research*, 62:448-455. <https://doi.org/10.2460/ajvr.2001.62.448>
- Mertes, H., Sawada, S.G., Ryan, T., Segar, D.S., Kovacs, R., Foly, J., Feigenbaum, H. 1993. Symptoms, adverse effects and complications associated with dobutamine stress echocardiography. Experience in 1118 patients. *Circulation*, 88:15-19.
- Minors, S.L., O'Grady, M.R. 1998. Resting and dobutamine stress echocardiography factors associated with the development of occult dilated cardiomyopathy in healthy Doberman Pincher dogs. *Journal of Veterinary Internal Medicine*, 12:369-380.
- Sahn, D.J., DeMaria, A., Kisslo, J., Weyman, A. 1978. Recommendations regarding quantitation in M-mode echocardiography: results of a survey of echocardiographic measurements. *Circulation*, 58:1072-1083.
- San Roman, J.A., Serrador, A., Ortega, J.R., Medina, A., Fernandez-Aviles, F. 2003. Diagnostic accuracy of a new shorter dobutamine infusion protocol in stress echocardiography. *Heart*, 89:1089-1090. <http://dx.doi.org/10.1136/heart.89.9.1089>
- Sandersen, C.F., Detilleux, J., deMoffarts, B., VanLoon, G., Amory, H. 2006. Effect of atropine-dobutamine stress test on left ventricular echocardiographic parameters in untrained warmblood horses. *Journal of Veterinary Internal Medicine*, 20:575-580. <https://doi.org/10.1111/j.1939-1676.2006.tb02899.x>
- Schinkel, A.F.L., Vourvouri, E.C., Bax, J.J., Boomsma, F., Bountiukos, M., Rizzello, V., Biagini, E., Agricola, E., Elhendy, A., Roelandt, J.R.T.C., Poldermans, D. 2004. Relation between left ventricular contractile reserve during low dose dobutamine echocardiography and plasma concentrations of natriuretic peptides. *Heart*, 90:293-296. <http://dx.doi.org/10.1136/hrt.2002.003822>
- Sousa, M.G., Carareto, R., Pereira-Neto, G.B., Gerardi, D.G., Camacho, A.A. 2004. Usefulness of dobutamine stress test in the evaluation of systolic function of dogs with doxorubicin induced cardiomyopathy. *Proceedings of 29th WSAVA, Free Communications, Rhodes, Greece, 6-8 October 2004*, <http://www.vin.com/proceedings/Proceedings.plx?CID=WSAVA2004&0=Generic>
- Sousa, M.G., Pereira-Neto, G.B., Carareto, R., Gerardi, D.G., Camacho, A.A. 2005 Assessment of eletrocardiographic parameters in healthy dogs undergoing dobutamine stress testing. *Schweizer Archive Fur Tierheilkunde*, 147:541-545. <https://doi.org/10.1024/0036-7281.147.12.541>.
- Spasojevic Kotic, Lj., Trailovic, D.R., Matunovic, R. 2012. Resting and dobutamine stress test induced serum concentration of brain natriuretic peptide in German Shepherd dogs. *Research in Veterinary Science*, 93:1446-1453. <https://doi.org/10.1016/j.rvsc.2012.04.002>
- Suzuki, R., Matsumoto, T., Teshima, T., Mochizuki, Y., Kozama, H. 2014. Dobutamine stress echocardiography for assessment of systolic function in dogs with experimentally induced mitral regurgitation. *Journal of Veterinary Internal Medicine*, 28:386-392. <https://doi.org/10.1111/jvim.12293>
- Tsutsui, J.M., Lario, F.C., Fernandes, D.R., Kowatsch, I., Sbrano, J.C., Franchini Ramires, J.A., Mathias, Jr.W. 2005. Safety and cardiac chronotropic responsiveness to the early injection of atropine during dobutamine stress echocardiography in the elderly. *Heart*, 91:1563-1567. <http://dx.doi.org/10.1136/hrt.2004.054445>
- Wackers, F.J.T. 1993. Which pharmacological stress is optimal, Editorial comment. *Circulation*, 87:646-648.

IZVODLJIVOST I EHOKARDIOGRAFSKE KARAKTERISTIKE TROMINUTNOG DOBUTAMIN STRES TESTA KOD ZDRAVIH PASA

SPASOJEVIĆ KOSIĆ Ljubica, TRAILOVIĆ R. Dragiša

Kratak sadržaj

Uvod. Dobutamin stres test se koristi kao metod funkcionalnog ispitivanja srca u medicini zbog efekata dobutamina koji su slični onima koje izaziva umerena fizička aktivnost. Cilj ovog istraživanja je bio da proceni izvodljivost i ehokardiografske karakteristike konvencionalnog DST kod pasa.

Materijali i metode. Deset klinički zdravih nemačkih ovčara je podvrgnuto konvencionalnom DST protokolu sa trominutnim intervalom aplikacije dobutamina (inicijalna doza od 7.5 µg/kg/min je povećavana svaka 3 minuta za 5 µg/kg/min do maksimalne doze od 42.5 µg/kg/min; maksimalno trajanje DST je bilo 24 minuta), a koji se koristi u medicini. Delovanje dobutamina je praćeno neinvazivnim dijagnostičkim metodima (simultano elektrokardiografijom i ehokardiografijom). Ehokardiografski parametri leve komore su mereni pre i na vrhuncu DST.

Rezultati i zaključak. Trajanje konvencionalnog DST kod pasa je bilo 19.4 ± 4.06 minuta. Tokom DST registrovana je tahikardija bez poremećaja srčanog ritma. Neželjeni efekti DST u ovom ispitivanju su bili uzbuđenje, dahtanje i slabost. Debljina međukomornog septuma u sistoli ($P=0.0093$) i dijastoli ($P=0.0080$) se značajno povećala na vrhuncu DST. Dimenzija leve komore na kraju sistole ($P=0.0077$) i indeks dijastolnog stresa zida leve komore ($P=0.0125$) su se značajno smanjili na vrhuncu DST. Trominutni interval sa povećanjem doze dobutamina je izvodljiv DST protokol kod pasa. Registrovane promene mogu da se objasne delovanju dobutamina preko β_1 adrenergičkih receptora. Ovaj farmakološki stres test izaziva značajne promene ehokardiografskih parametara leve komore kod odraslih zdravih pasa. Psi ispoljavaju prolazne znake sinusne tahikardije, uzbuđenja, dahtanja i slabosti tokom DST. Dodatna ispitivanja DST treba da procene dijagnostički značaj ovog protokola kod pasa koji pate od srčanih oboljenja.

Ključne reči: dobutamin, ehokardiografija, farmakološki stres test, pas