

## **EQUINE ACQUIRED INGUINAL HERNIATION – DIAGNOSIS AND TREATMENT IN 62 CASES**

KOVAC Milomir<sup>1\*</sup>, ALIEV Ruslan<sup>1</sup>, IPPOLITOVA Tatjana<sup>1</sup>, TAMBUR Zoran<sup>2</sup>

<sup>1</sup>Moscow State Academy of Veterinary Medicine and Biotechnology named after K.I. Scriabin, Equine Clinic – New Century, Moscow, Russia; <sup>2</sup>Military Medical Academy, Institute of Hygiene, Belgrade, Serbia and Faculty of Stomatology in Pančevo, Pančevo, Serbia

Received 28 December 2017; Accepted 03 April 2018

Published online: 30 April 2018

Copyright © 2018 Kovac et al. This is an open-access article distributed under the Creative Commons Attribution License, which permits unrestricted use, distribution, and reproduction in any medium, provided the original work is properly cited.

### **Abstract**

*Introduction.* The medical records of 62 stallions with acquired inguinal herniation were reviewed (2007-2017).

*Materials and Methods.* The history, clinical and laboratory findings on admission to the clinic and methods of treatment have been summarized.

*Results and Conclusions.* The prevalence of inguinal hernia among horses with colic was 3.85 % (62/1609 cases). Indirect inguinal hernia was observed in 58 cases (93.54 %) and incarcerated inguinal hernia was observed in 55 horses (88.71 %). Hernia was found more frequently on the left side (36 cases) than on the right (26 cases). The majority of horses with acquired inguinal hernia were admitted to the clinic in the summer and spring (49/62), i.e. when air temperatures were high, significantly more ( $p < 0.05$ ) than in winter or autumn (13/62). Comparing the breed proportion of hernia cases with other horses with colic, disproportionately high percentages of trotter and thoroughbred horses were found with acquired inguinal herniation. Significant differences of the clinical and laboratory blood parameters were found when more time had passed from the onset of colic until the horses' arrival at the clinic. There was a significant positive correlation between the duration of colic and the onset of gastric reflux, increase of hematocrit and heart rate. Six horses were conservatively and 55 horses surgically treated. The clinic discharge rate was 90.32% (56/62). Early diagnosis and admission to the veterinary clinic and emergency surgery is necessary for equine inguinal hernia. The conservative treatment was successful only in cases of incarcerated inguinal hernia with colic duration less than 4 hours. Equine acquired inguinal herniation carries a good prognosis if the affected horse is rapidly taken to a specialized facility where a conservative or surgical correction is performed promptly.

**Key Words:** acquired inguinal hernia, horse, diagnosis, treatment

---

\*Corresponding author – e-mail: kovacmilomir@gmail.com

## INTRODUCTION

Inguinal/scrotal herniation occurs when intestine protrudes through the vaginal ring into the inguinal canal with descent into the scrotum. Thus, the two terms (inguinal and scrotal hernia) have been used interchangeably (Mezerová et al. 2008). In the majority of cases of equine inguinal herniation, the small intestine, usually the ileum or distal jejunum, is herniated (Coelho, 2009). Extremely rarely, the large intestine, omentum or urinary bladder protrude into the inguinal canal (Cousty, 2009; Robinson & Carmalt, 2009). Indirect hernia is the most common form of inguinal hernia in horses, with the herniated intestine within the tunica vaginalis (Mezerová et al., 2007). Direct inguinal hernia is less common in horses, primarily with intestine entering exterior to the vaginal tunic. This occurs either through a rent in the fascia of the abdominal wall adjacent to the vaginal ring or by a rupture of the vaginal process (Van der Velden, 1988a). The equine inguinal/scrotal hernias can be congenital or acquired. Congenital inguinal hernias, which are normally seen in one- to four-day-old foals, are usually reducible, bilateral and not accompanied by signs of colic (Spurlock & Robertson, 1988). In contrast, acquired inguinal herniation primarily occurs in adult stallions, and is extremely rare in geldings, because their vaginal rings decrease in size soon after castration (Bartmann & Brickwede, 1999).

In most cases of acquired inguinal herniation, the herniated small intestine is strangulated at the site of the vaginal ring (*hernia inguinalis incarcerata*), resulting in vein congestion and wall necrosis of the intestine. This form of hernia causes clinical signs of abdominal discomfort, i.e. moderate to severe colic. In most incarcerated inguinal hernias, the vaginal ring (*anulus vaginalis*) is the site of herniation, but not the site of incarceration (Huskamp & Kopf, 1997). Two factors influence the formation and incarceration of the hernia, due to the anatomical formation of the inguinal annulus and canal, the so-called “funnel effect” and “hour-glass effect”. Incarceration is usually located 2-3 cm distant from the funnel-shaped vaginal annulus, at the infundibulum, where the inguinal canal narrows in an hour-glass-like way. At this place, internal spermatic fascia turns into cellular tissue (Toth & Hollerieder, 2002). Additionally, in the majority of cases, irreducible inguinal herniation causes compression and occlusion of the testicular vessels inside the vaginal cavity, and therefore, the affected testis quickly becomes firm, edematous, macerated, or even necrotic (Van der Velden, 1988b).

In the present study we reviewed the diagnosis, symptoms, and treatment obtained in 62 cases of acquired inguinal hernia. The purpose of the study was to gain a better insight into the prevalence and improved results of the treatment of equine acquired inguinal hernia.

## MATERIALS AND METHODS

The medical records of 62 horses with acquired inguinal herniation, selected from the 1609 other colic cases that had been treated at the Equine Clinic – New Century of the

Moscow State Academy of Veterinary Medicine and Biotechnology, Moscow, during the period from 2007 to 2017, were reviewed. The history, clinical and laboratory findings at admission in the clinic, and methods of treatment have been summarized.

All the horses were clinically examined (rectal temperature, heart and respiratory rate) and laboratory parameters (hematocrit, total plasma protein, blood pH, base excess, bicarbonate concentration) were collected immediately upon admission to the equine clinic. Hematocrit was analyzed by a capillary microcentrifuge using venous blood. Total serum protein (TPP) was measured with a refractometer. Blood gas analysis (pH blood, base excess, bicarbonate concentration) was by a Radiometer ABL 5 (Radiometer Medical A/S, Copenhagen, Denmark).

Conservative and surgical treatment procedures are described below.

Statistical analysis: The computer software Statistics Analysis System, SAS 9 was used for the computation of statistical data. Student's t-test,  $\alpha=0.05$  was used to compute quantitative variables. Qualitative variables were computed with the Chi-squared test. Statistical dependencies between the clinical and laboratory parameters and duration of the colic were examined with Pearson's correlation tests.

## **RESULTS**

During the period from 2007 to 2017, 1609 colic horses were admitted and treated in the equine clinic. From these horses with gastro-intestinal disease, diagnoses of acquired inguinal herniation were made in 62 cases, i.e. the prevalence of this disease among horses with colic was 3.85 %. This form of hernia was much more common in horses than the congenital hernias, which had a prevalence of 0.19 % (3/1609). From 62 horses with acquired inguinal herniation, indirect hernia was observed in 58 cases (93.55 %) and only 4 horses (6.45 %) had direct inguinal hernia (1 case with a rupture of the vaginal process and 3 cases with a rupture of fascia in the abdominal wall). A strangulated, non reparable form of hernia was observed in 55 of 62 horses (88.71%) and only in 7 animals was a reparable, non strangulated form of inguinal hernia observed. The affected inguinal side was not equally distributed (36 left, 26 right).

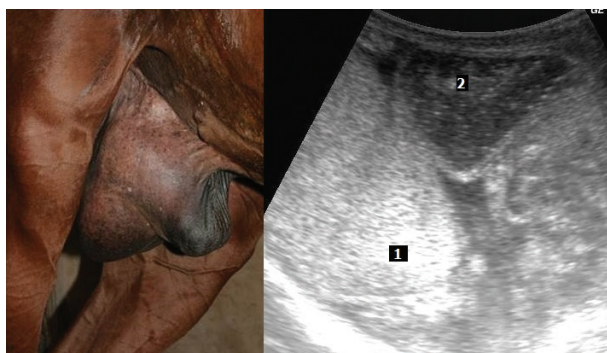
The majority of horses with acquired inguinal herniation came to the clinic in the summer and spring (49/62), i.e. when air temperatures were high, significantly more ( $p<0.05$ ) than in winter or autumn (13/62). Cases of inguinal hernia were mostly encountered in August.

Horses with acquired inguinal herniation were of the following breeds: 9 Hanoverian, 8 Orlov Trotter, 8 Trakehner, 8 Russian Saddle Horse, 7 Thoroughbred, 6 Standardbred, 3 Andalusian, 4 Budyonny Horse, 3 Draft horse, 2 Arab, 2 Dutch Warmblood and 1 Pony. Compared with the breed proportion of other horses admitted to the clinic with colic, we observed disproportionately high percentages of trotter and thoroughbred in horses with acquired inguinal herniation. The average age of horses with acquired inguinal herniation was 6.7 years ( $\pm 3.78$ ), range from 2-21 years.

All the animals with strangulated inguinal herniation had a history of colic of varying severity. In approximately 90 % of cases at admission to the clinic, these horses showed moderate or severe grade of colic symptoms. The majority of horses without colic symptoms were treated by other veterinarians before their admission to the clinic, using strong analgetic or sedative medicaments (flunixin meglumine, butorphanol, detomidine).

The duration of colic in horses with incarcerated inguinal hernia, i.e. in horses with strangulated hernia, the time of admission to the clinic varied from 2 to 25 hours after colic was first observed (mean  $8.9 \pm 4.98$  hours). The duration of colic in horses with acquired non incarcerated inguinal hernia (reparable hernia) varied from 1 to 87 days (mean  $24.6 \pm 21.18$  days).

Equine inguinal hernia was easily diagnosed in 61/62 cases, through a combination of clinical, rectal and ultrasound techniques. Scrotal palpation in most affected horses (52/62) revealed a large painful form of irreducible swelling. The percutaneous scrotal sonogram in most horses showed an intestinal loop which had moved into the scrotal bag close to the testicle (Fig. 1). On rectal examination of 51 horses (in 11 horses this was not performed), a small intestinal loop entering the inguinal canal and sometimes also multiple distended small intestinal loops in the caudal part of the abdominal cavity could be palpated. Nasogastric intubation was performed in 49 horses. No reflux was obtained in 36 horses, while the remaining five yielded 2-24 L of gastric content (mean  $4.2 \pm 1.4$  L). There was a significantly positive correlation between the colic duration and the onset of gastric reflux. If the colic duration was less than 7 hours, gastric reflux did not occur.



**Figure 1.** Ultrasonographic image of scrotum in a horse with hernia inguinalis incarcerate, 1. Testis, 2. Small intestine

Average clinical and laboratory parameters found on first examination in the equine clinic of horses with acquired inguinal herniation are summarized in Table 1. In cases of incarcerated inguinal hernia, we found significant differences in the clinical and laboratory indicators of equine blood when more time had passed from the onset of colic until the arrival at the clinic. The heart rate of horses with incarcerated inguinal

hernia (mean  $68.6 \pm 12.12$  beats/min, range 40-96) was significantly higher ( $p < 0.05$ ) than horses with non incarcerated inguinal hernia (mean  $40.4 \pm 7.09$  beats/min). The temperature and respiratory rate in horses with incarcerated inguinal hernia were not significantly higher than in with horses without strangulation (Table 1). Mean hematocrit of horses with incarcerated inguinal hernia on admission to the clinic was  $0.45 \pm 0.07$  L/L, which was significantly higher ( $p < 0.05$ ) than in horses with non incarcerated inguinal hernia. Additionally, the horses with incarcerated inguinal hernia had moderate metabolic acidosis (Table 1).

There was a positive stark correlation between the duration of colic and the hematocrit (the correlation coefficient,  $r = 0.72$ ) and the heart rate ( $r = 0.69$ ), but not with the respiration rate ( $r = 0.52$ ), the temperature ( $r = 0.13$ ), the concentration of total plasma protein ( $r = 0.34$ ) or the  $\text{HCO}_3$  ( $r = -0.42$ ) in horses with incarcerated inguinal hernia.

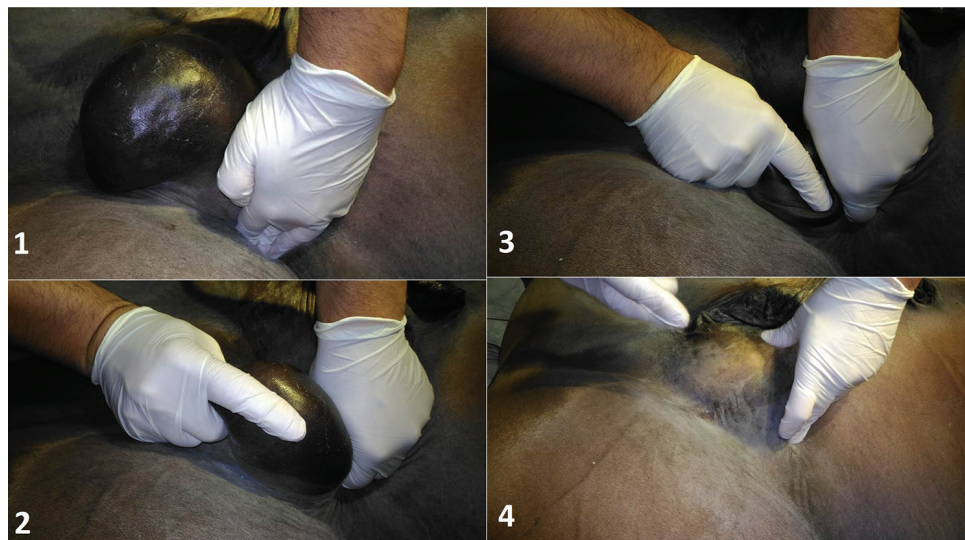**Table 1.** The clinical and laboratory parameters of horses with acquired inguinal herniation on admission to the clinic

Parameters	Hernia inguinalis incarcerated (55 cases)	Hernia inguinalis non incarcerated (7 cases)
Heart rate (beats/min)	$68.6 \pm 12.12$	$40.4 \pm 7.09^*$
Respiration rate (inhalations/min)	$22.4 \pm 6.90$	$18.43 \pm 4.36$
Total Plasma Protein (g/L)	$68.5 \pm 11.35$	$65.46 \pm 8.28$
Hematocrit (L/L)	$0.45 \pm 0.07$	$0.40 \pm 0.05^*$
$\text{HCO}_3$ (mmol/L)	$23.46 \pm 4.94$	$25.24 \pm 5.01$
Base excess (mmol/L)	$-0.27 \pm 1.02$	$3.56 \pm 1.77^*$
Temperature ( $^{\circ}\text{C}$ )	$37.8 \pm 0.61$	$37.7 \pm 0.95$

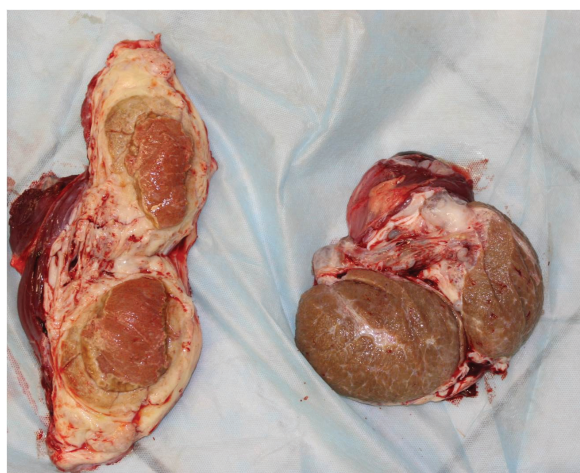
\* =  $p < 0.05$

Treatment of horses: Among 62 horses with acquired inguinal hernia, conservative treatment was performed in 6 animals and 56 patients were operated on. The conservative treatment was conducted only in cases of incarcerated inguinal hernia with colic duration less than 4 hours. In these cases, during general anesthesia, horses were placed in dorsal recumbency and manual reduction of scrotal hernias (external massage) was performed. The affected testis was several times manually descended through the inguinal canal into the abdominal cavity, and then returned back to the scrotum, with the purpose of facilitating the tension and releasing the incarceration of the small intestine (Fig. 2). With this method, we achieved successful treatment in 5 of 6 horses. According to our early clinical experience, this method of treatment would not be successful in any horse with inguinal intestinal incarceration with a duration of more than 6 hours. Among the five horses with conservative treatment, we additionally castrated three horses on the affected side. In one horse without castration, orchitis was diagnosed one week after the treatment and for this reason this horse was also castrated three weeks later (Fig. 3). In horses where it was impossible to

assess strangulation of the intestine manually, we immediately performed the surgical treatment.



**Figure 2.** The conservative treatment of hernia inguinalis incarcerata with external massage of scrotum, **1.** Palpation of superficial inguinal ring, **2.** and **3.** Affected testis manually descended through the inguinal canal into the abdominal cavity, **4.** Testis in the abdominal cavity



**Figure 3.** Removed testes after castration of a horse with orchitis (left); right a normal testis

All the horses with incarcerated inguinal hernia and with colic duration more than 4 hours were immediately operated on after the admission to the clinic. Other horses with non incarcerated inguinal hernia also underwent surgical treatment under general anesthesia, but not immediately; in most cases, surgery was performed the day following their admission to the clinic.

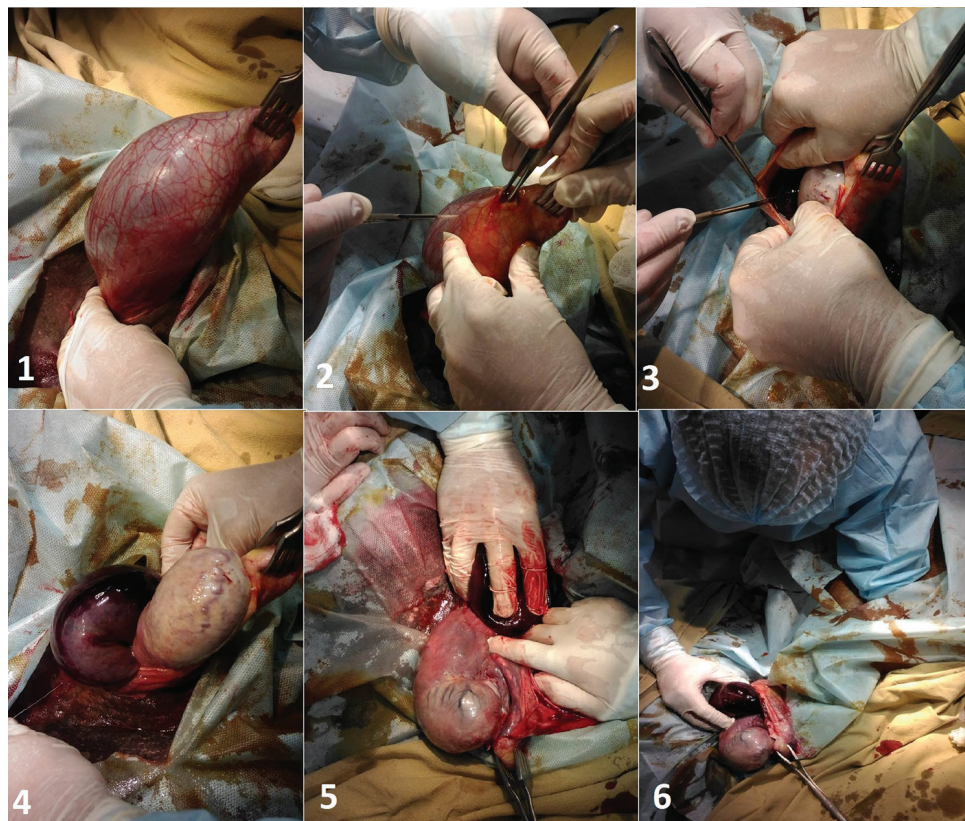
The surgical method was dependent on duration of colic disease and the form of the acquired inguinal hernias. If the time from the onset of the disease to the surgical intervention was not more than 7 hours, we more often applied only the inguinal surgical approach. In these cases, the inguinal-scrotal and ventral midline areas were prepared for aseptic surgery. A 10 cm length skin incision was made starting at the cranial edge of the superficial inguinal ring and running a little distally over the scrotum. The affected testis and the vaginal sac with its contents were freed from the scrotum. The parietal vaginal tunic was incised carefully to expose the herniated loop of small intestine contained within. In horses without damage of the herniated intestine, we gently replaced intestine through the vaginal ring into the abdomen by digital pressure, and the testicle in the affected site was removed immediately using the half-closed castration method. The superficial inguinal ring, the subcutaneous tissues and the skin were closed.

In cases of equine incarcerated inguinal hernia, where it was impossible to push the intestine into the abdomen through the vaginal ring, a midline celiotomy was performed immediately. After that, from the inside of the abdomen, intestinal loop from the inguinal canal was gently manually returned into the abdomen (Fig. 4). If the replacement was difficult or impossible (in 26 cases; the majority of horses were with strangulation of ileum), a blunt-pointed scalpel was inserted into the cranio-lateral aspect of the vaginal cavity, guided by one finger of the other hand to avoid injury of the intestine, and the vaginal ring was incised carefully in a cranial direction, i.e. a herniorrhaphy was performed. After incising the vaginal ring, following replacement of the intestine through the inguinal ring, the affected segment and the remainder of the ileum and jejunum were exteriorized in loops through the celiotomy incision to check for nonviable areas. Severe thickening of the intestinal wall, a purple-black color, lack of movement after pinching and thrombosis of the mesenteric vessels were considered as the indicative loss of intestinal segment viability. After the exploration of abdominal cavity we observed that the jejunum alone was involved in 29 horses, the ileum in 18 horses and the jejunum and ileum in 10 horses. The length of incarcerated intestine varied from 10 to 150 cm. In five horses with positive conservative treatment it was impossible to know which part of the small intestine was affected.

During the surgical treatment in most horses with acquired inguinal hernias only the small intestinal reposition and sometimes decompression of small intestine was also performed. If the small intestinal loop appeared to be non-viable, a resection and anastomosis from small intestine was undertaken. According to retrospective study data, there were 13 horses with small intestinal resection of different lengths (1-11 meters/ mean  $1.75 \pm 0.8$  meters). End-to-end jejuno-jejunal anastomosis was performed in nine horses (Fig. 5), two horses had jejunocecostomy and two horses had end-to-end jejuno-ileal anastomosis. All these horses had had more than 7 hours of colic before surgical treatment.

The right displacement of colon ascendens was additionally diagnosed intraoperatively in a stallion presenting in our retrospective study for surgical correction of an acquired

inguinal hernia. In this horse, the small intestinal resection was undertaken and additionally a reposition of the colon ascendens intraoperatively performed.



**Figure 4.** Surgical treatment in a horse with hernia inguinalis incarcerata, **1.** Affected testis with strangulated intestine, **2.** and **3.** Incision of the parietal vaginal tunic, **4.** Herniated loop of the small intestine after incision of the parietal vaginal tunic, **5.** Replacing intestine through the vaginal ring into the abdomen by external digital pressure, **6.** Replacing intestine from the inguinal canal into the abdomen after midline celiotomy.

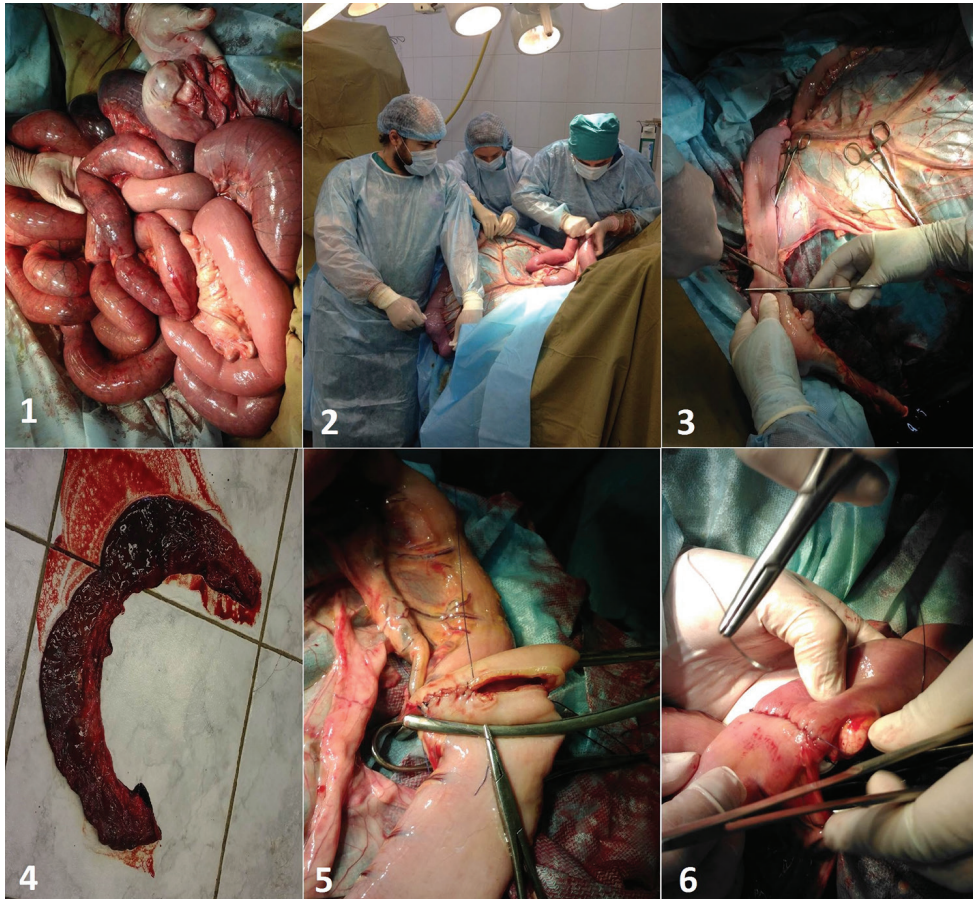All surgical horses with incarcerated inguinal hernia were additionally castrated bilaterally or unilaterally on the affected side.

In cases of very extensive damage of the small intestine, i.e. more than 11 m, two horses due to poor prognosis and one horse for financial reasons, were euthanized during the operation. All these horses had colic for more than 12 hours.

All horses recovered from general anesthesia after surgery. After that, standard methods of therapy post-equine abdominal surgery were implemented for 7 to 10 days (i.e., infusion 3-5 days, application of prokinetic medicaments, antibiotics and NSAIDs, and controlled feeding) (Kovac et al., 2008; 2015). Scrotal swelling associated with edema formation occurred in 14 horses, and in 11 horses, edematous swelling and purulent discharge from the incision wound developed one week post-operatively, but



were treated successfully by conservative methods. Reduced defecation and paralytic ileus were noted in 16 horses following abdominal surgery. There was a significant positive correlation between colic duration and the onset of paralytic ileus ( $r = 0.63$ ). One of these horses underwent a second celiotomy three days following the initial surgery, when severe colic had recurred. Two horses with paralytic ileus and one horse with peritonitis were euthanized on days 9, 12 and 21. Other animals recovered well, and 56 horses were discharged 4-19 days following surgery. The clinic discharge rate was 90.32% (56/62).



**Figure 5.** Resection of the small intestine and end-to-end jejunostomy in a horse with hernia inguinalis incarcerata, **1.** Checking for nonviable areas of the ileum and jejunum through the celiotomy incision, **2.** Decompression of the distended loops of the small intestine, **3.** and **4.** Resection of the small intestine, **5.** Schmieden's suture, **6.** Lembert suture.

One horse that had not had surgical treatment (i.e. underwent conservative treatment) was operated on 6 months later for chronic colic. Adhesion ileus on the transition between the jejunum and ileum had developed in this horse. A small intestinal

resection and jejunio-ileal anastomosis was performed, and the horse recovered slowly but successfully.

According to follow-up contact was made by telephone 6-12 months following discharge, 46 of 56 horses released from the clinic returned to their previous levels of exercise and did not show any recurrent colic episodes later.

## DISCUSSION

Acquired inguinal hernias after umbilical hernia are the second most frequent type of hernia diagnosed in horses (Schneider et al., 1982). For the reasons of strangulation of the small intestine, the incarcerated inguinal hernia is the most dangerous form, is a relatively common cause of acute colic pain, and without emergency treatment it is a life-threatening condition in stallions (Huskamp & Kopf, 1997; Mezerová et al., 2003). In our retrospective study, the prevalence of acquired inguinal hernias in horses with colic admitted to our clinic was 3.79 %. It was much more common than congenital inguinal hernia that had a prevalence of 0.372 %. The prevalence of equine inguinal hernia reported in other studies ranges from 0.45-5.1% (Spurlock & Robertson, 1988; Van der Velden, 1988; Toth & Hollerrieder, 2002).

The cause of acquired inguinal hernia is not well known. These hernias typically occur in stallions with enlarged internal inguinal ring, often following an event which produces an increased intra-abdominal pressure such as copulation, strenuous exercise, trauma and routine castration complications (Weaver, 1987; Wilderjans et al., 2007). According to our observations a high air temperature and genetic factors (high prevalence in trotters breed horse) also play an important role in the onset of this condition. One of the reasons may be a congenitally enlarged vaginal ring. This was confirmed by earlier studies (Schneider et al., 1982; Spurlock & Robertson, 1988).

Different surgical approaches have been described in correction to inguinal hernias. In some horses the hernia will spontaneously resolve during anesthetic induction and positioning on the surgery table, whereas other hernias must be manually reduced by gentle traction and a twisting motion on the testicle during anesthesia, with the horse poisoned in dorsal recumbency. As the interval from the onset to the initiation of the treatment lengthens to more than 4 hours, the strangulated intestine becomes more edematous, and the conservative therapy will be less likely to be successful.

After this period, the successful return of the intestine inside the abdominal cavity was rare, and this nonsurgical correction will often result in the returning small intestine having considerable damage. In these cases, the possibility of developing paralytic or adhesion ileus is very high. Significant damage of small intestine very rarely could happen within 4 hours from the onset of the strangulated hernia inguinalis. Additionally, we do not recommend the treatment of the hernia inguinalis per rectum with traction on the bowel, as there is a very high risk of the rectum being perforated. In horses with longer periods of colic (> 4 hours from the onset colic), only surgical interventions

of the strangulated hernia iniquinalis are effective; they are also more reliable. We prefer to make the first attempt of the reposition of the intestine through the inguinal approach. If the desired result is not obtained this way, the second chosen approach is a ventral midline incision with a herniotomy. In cases of the loss of viability and necrosis of a segment of the small intestine, a resection or bypass procedure such as a jejunocecostomy or jejunoileostomy is required for definitive, successful treatment.

The testicle on the affected side is usually already compromised in the early phase of incarcerated inguinal hernia so unilateral castration is necessary. Testicular atrophy or severe inflammation with adhesion often develops, if the testicle is not removed (Toth & Hollerieder, 2002). To prevent the recurrence of inguinal herniation in adult stallions, unilateral or bilateral castration is also recommended. However, in many cases, the testicle is still viable and the owner wishes to keep the stallion for breeding. In these cases, the size of the vaginal ring should be restricted to avoid recurrence. This can be performed by a laparoscopic inguinal herniorrhaphy. There are several techniques at the moment using staples and sutures, meshes, superglue, barbed sutures or a peritoneal flap to partially close or cover the vaginal ring (Marien, 2001; Rossignol et al., 2007; Wilderjans et al., 2007; Reagle et al., 2013; Rossignol et al., 2014).

The mortality rate from acquired inguinal hernias in our retrospective study is under 10 %. The mortality rate in other studies varies considerably from 20-62 % (Schneider, 1982; Huskamp & Kopf, 1997; Toth & Hollerieder, 2002; Mezerová et al., 2008). The explanation for the different mortality rates reported is complicated. Survival was significantly influenced by the type of intestine lesion (strangulated, non-strangulated), duration of colic, experience of surgeons, anesthetic duration, and especially, postoperative care. New methods in the treatment of equine postoperative paralytic ileus clearly improve the survival rate of horses after colic operations (Kovac, 2008; 2015). Apart from variability of veterinary care, attitudes towards euthanasia vary among the countries, which may bias the outcomes. According to our observation, early diagnosis and admission to the equine clinic and emergency surgery significantly decrease the mortality rate in cases of equine inguinal hernia. If the strangulation of the small intestine has been present for a number of hours, more marked compromise or devitalization of the affected intestinal segment and development of severe endotoxic shock would be expected with grave prognosis. In other words, acquired inguinal herniation carries a good prognosis if the affected horse is rapidly taken to a specialized facility, where a conservative or surgical correction is performed promptly.

### **Authors contributions**

KM conceived and planned the study. AR carried out the study. IT took the lead in writing the manuscript. TZ participated in the statistical analysis.

### **Competing interests**

The authors declare that they have no competing interests.

## REFERENCES

- Bartmann C. P., Brickwede I. 1999. Kolik durch Hernia inguinalis bei einem Wallach. *Pferdeheilkunde*, 4:19-322.
- Coelho C. S. 2009. Retrospective study of inguinal hernia in horses: 28 cases. *Proceedings of 11th Congress of the World Equine Veterinary Association*. São Paulo. 27.
- Cousty M. 2010. Inguinal rupture with herniation of the urinary bladder through the scrotal fascia in a Shetland pony foal. *Equine Veterinary Education*, 22:3-6. <https://doi.org/10.2746/095777309X462>
- Huskamp B., Kopf N. 1997. Hernia inguinalis incarcerata beim Pferd. *Der Praktische Tierarzt*, 78:217.
- Kovac M., Aliev R., Elizarova O., Ivanyatov E. 2015. Etiology, diagnosis and treatment of equine post operation paralytic ileus. *VetPharma*, 4:26-28.
- Kovac M., Huskamp B., Toth J. 2008. Prevalence, risk and therapy of postoperative ileus after intestinal surgery in the horse – *Proceedings of 10th Congress of the World Equine Veterinary Association*, Moscow, 56.
- Marien, T. 2001. Standing laparoscopic herniorrhaphy in stallions using cylindrical polypropylene mesh prosthesis. *Equine Veterinary Journal*, 33:91-99. <https://doi.org/10.2746/042516401776767476>
- Mezerová J., Zdenek Z., Kabel R., Petr J. 2003. Hernia inguinalis incarcerata in horses: 43 cases. *Pferdeheilkunde*, 19:263-268.
- Mezerová J., Zert Z., Kabes R., Ottova L. 2008. Analysis of therapeutic results and complications after colic surgery in 434 horses. *Veterinarni Medicina* 53, 12-28.
- Reagle C. A., Yiannikouris S., Tibary A. A., Fransson B. A. 2013. Use of a barbed suture for laparoscopic closure of the internal inguinal rings in a horse. *Journal of the American Veterinary Medical Association*, 242:249-253. <https://doi.org/10.2460/javma.242.2.249>
- Robinson E, Carmalt J. L. 2009. Inguinal Herniation of the ascending colon in a 6-month-old Standardbred colt. *Veterinary Surgery*, 38:1012–1013. <https://doi.org/10.1111/j.1532-950X.2009.00595.x>
- Rossignol F., Perrin R., Boening K.J. 2007. Laparoscopy hernioplasty in recumbent horses using transposition of a peritoneal flap. *Veterinary Surgery*, 36:557-562. <https://doi.org/10.1111/j.1532-950X.2007.00282.x>
- Rossignol F., Mespoulhes-Rivière C., Vitte A., Boening K. J. 2014. Standing laparoscopic inguinal hernioplasty using cyanoacrylate for preventing recurrence of strangulated inguinal herniation in 10 stallions. *Veterinary Surgery*, 43:6-11. <https://doi.org/10.1111/j.1532-950X.2013.12083.x>
- Schneider R. K., Milne D. W., Kohn C. W. 1982. Acquired inguinal hernia in the horse: a review of 27 cases. *Journal of the American Veterinary Medical Association*, 180:317-320.
- Spurlock G. H., Robertson J. T. 1988. Congenital inguinal hernias associated with a rent in the common vaginal tunic in five foals. *Journal of the American Veterinary Medical Association*, 193:1087-1088.
- Toth J., Hollerrieder J. 2002. Diagnosis and treatment of hernia inguinalis incarcerata. *Magyar Allatorvosok Lapja*, 124:71-81.
- Van der Velden M. A. 1988a. Surgical treatment of acquired inguinal hernia in the horse: a review of 51 cases. *Equine Veterinary Journal*, 20:173-177. <https://doi.org/10.1111/j.2042-3306.1988.tb01491.x>

- Van der Velden M. A. 1988b. Ruptured inguinal hernia in new-born colt foals: a review of 14 cases. *Equine Veterinary Journal*, 20:178-181. <https://doi.org/10.1111/j.2042-3306.1988.tb01492.x>
- Wilderjans H., Simon O., Boussauw B. 2008. Strangulated hernias in 63 horses. Results of manual closed nonsurgical reduction followed by a delayed laparoscopic closure of the vaginal ring. In: *Proceedings of the 10<sup>th</sup> International Congress of World Equine Veterinary Association*, January 28 – February 1, 2008, Moscow, Russia, 360–364.
- Weaver D. 1987. Acquired incarcerated inguinal hernia: A review of 13 horses. *Canadian Veterinary Journal*, 28:195-199.

## STEČENA INGVINALNA HERNIJA KOD KONJA – DIJAGNOZA I TERAPIJA KOD 62 SLUČAJA

KOVAČ Milomir, ALIEV Ruslan, IPPOLITOVA Tatjana, TAMBUR Zoran

### Kratak sadržaj

*Uvod.* Urađeno je retrospektivno ispitivanje 62 pastuva sa stečenom ingvinalnom hernijom (2007-2017).

*Materijal i metode.* Rezimirani su anamnestički, klinički i laboratorijski nalazi kod konja prilikom prijema u kliniku, dijagnostika i lečenje.

*Rezultati i zaključak.* Prevalencija ove bolesti bila je 3,85% (62/1609 slučajeva). U 58 slučajeva (93,54%) dijagnostikovana je indirektna ingvinalna hernija, a kod 55 konja (88,71%) utvrđena je ukleštena ingvinalna hernija. Ingvinalna hernija se češće primećivala na levoj strani (36 slučajeva), u odnosu na desnu stranu (26 slučajeva). Stečena ingvinalna hernija se češće dešavala u leto i proleće (49/62), odnosno pri visokim temperaturama vazduha, značajno više ( $p < 0,05$ ) nego zimi ili u jesen (13/62). Nesrazmerno visok procenat obolelih konja primećen je u kasača i punokrvnih konja. Značajne promene kliničkih i laboratorijskih parametara evidentirane su kod konja kod kojih bolest ima produžen tok. Postoji signifikantna pozitivna korelacija između trajanja oboljenja u odnosu na pojavu refluksa želuca, kao i povećanja hematokrita i srčane frekvencije. Konzervativno je zbrinuto 6 konja, a 55 hiruški. Procenat izlečenja konja bio je 90,32% (56/62). Kratko trajanje oboljenja, rana dijagnoza i hitno hiruško lečenje znatno smanjuje smrtnost od ukleštene ingvinalne hernije. Konzervativno lečenje bilo je uspešno samo u slučajevima kada ukleštenje nije trajalo duže od 4 časa.

**Ključne reči:** hernija ingvinalis, konj, dijagnoza, lečenje