

HYPERSENSITIVITY IN A DOG ACCOMPANIED BY GENERALISED ONYCHODYSTROPHY

KOTNIK Tina*

University of Ljubljana, Veterinary Faculty, Small Animal Clinic, Ljubljana, Slovenia

Received 08 September 2017; Accepted 03 April 2018

Published online: 16 April 2018

Copyright © 2018 Kotnik. This is an open-access article distributed under the Creative Commons Attribution License, which permits unrestricted use, distribution, and reproduction in any medium, provided the original work is properly cited

Abstract

Canine food hypersensitivity and canine atopic dermatitis are two of the most common allergic diseases in dogs. Food hypersensitivity is typically non-seasonal reaction of types I, III and IV, directed most commonly against glycoproteins in the foods. Canine atopic dermatitis is a genetically predisposed inflammatory and pruritic allergic skin disease with characteristic clinical features associated with IgE most commonly directed against environmental allergens. Irrespective of allergens that dogs are sensitised to, clinical symptoms in acute cases involve pruritus with erythema of the skin around lips, axillae, inguinal and perianal region or feet as well as external ear canal inflammation. In chronic cases, consequences of self-trauma and secondary bacterial or fungal infections may be present as excoriations, lichenification and hyperpigmentation. Hypersensitivity can have a strong impact on quality of life of diseased dogs as well as of their owners.

A mixed breed female dog with heavily expressed generalised onychodystrophy accompanied by mild erythema of the groin and external ear canals, which responded to elimination diet and allergen-specific immunotherapy, is presented.

Key Words: onychodystrophy, CAD, food hypersensitivity, dog, ASIT

CASE PRESENTATION

A mixed breed female dog, 7 years old, adopted when 3 years old, was presented to the Small Animal Clinic of Ljubljana's Veterinary Faculty due to intensive licking of the paws, accompanied by nail fragility (Figure 1). Symptoms were first noticed in summer 2015 when the dog was 6 years old. The problem spontaneously ceased in autumn 2015 and reappeared in spring the next year. Besides onychodystrophy, sneezing, eye discharge, and frequent mucoid stool were noticed by the owner. Dystrophic nails of

*Corresponding author – e-mail: tina.kotnik@vf.uni-lj.si

all feet and mildly erythematous skin of external ear canals and groin were noticed during the clinical examination (Figure 2). Thyroid hormones were in the normal range. Culture of the nail swab revealed the presence of *Staphylococcus pseudintermedius*. According to antibiotic sensitivity test results, the dog was treated with amoxicillin + clavulanic acid and non-steroid anti-inflammatory drugs with transient improvement. Some of the dystrophic nails were surgically removed. At this point, the diet was changed from commercial dry foods to a home cooked, individually tailored diet. Methylprednisolone treatment at doses of 0.8 mg/kg once daily for 7 days and then 0.5 mg/kg every other day for 45 days was commenced. Sneezing, eye discharge, and erythema of the skin ceased, but the nails showed no improvement and the owner still occasionally noticed mucoid stool. Improvement of some nails was evident after 3 months of elimination diet when the stool was also back to normal (Figures 3-4). At this point, intradermal skin testing was performed which revealed sensitization to weed pollen mixture, plane tree, pigeon feather and the storage mite *Lepidoglyphus destructor*. After challenge with dairy products and fruits, erythematous otitis reappeared. Allergen-specific immunotherapy (ASIT) was then started during winter 2016 (Figures 5-7). No side effects were noticed but the majority of the nails reverted to normal. In spring 2017, one nail on a back foot was found to be broken together with mild pruritus of the groin. Vitamin E (E-OIL; Natural Wealth) was added to the therapy at a dose of 8 IU/kg once daily.

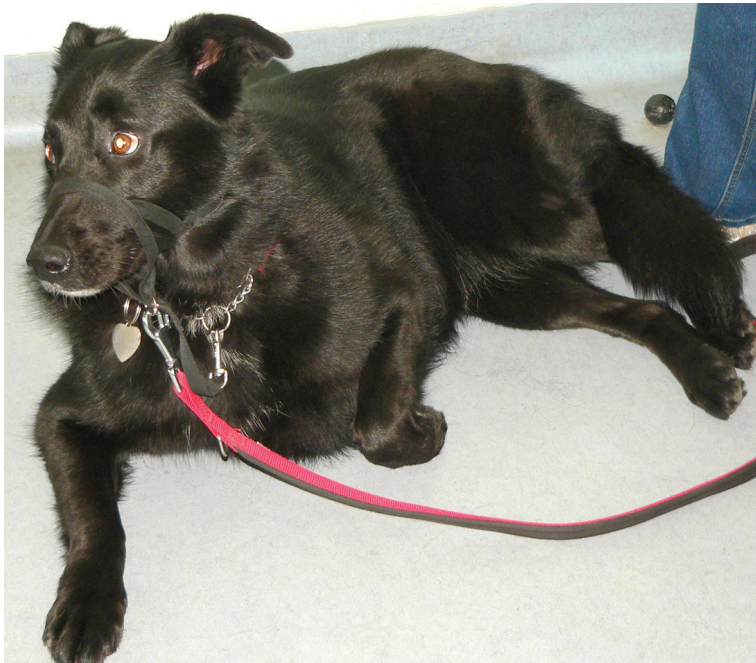

Figure 1. Mixed female dog at the first presentation

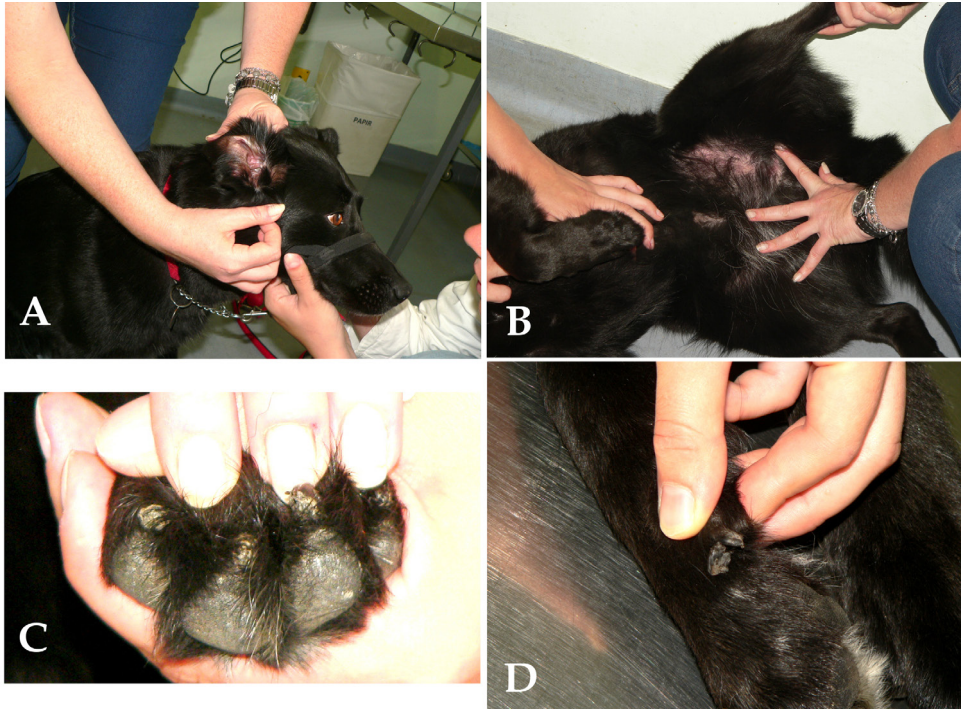


Figure 2. A. Erythema of the skin of the ears at the first presentation; B. Erythema of the skin in the groin at the first presentation; C. Nails of the feet before the treatment; D. Slaughtering of the nail

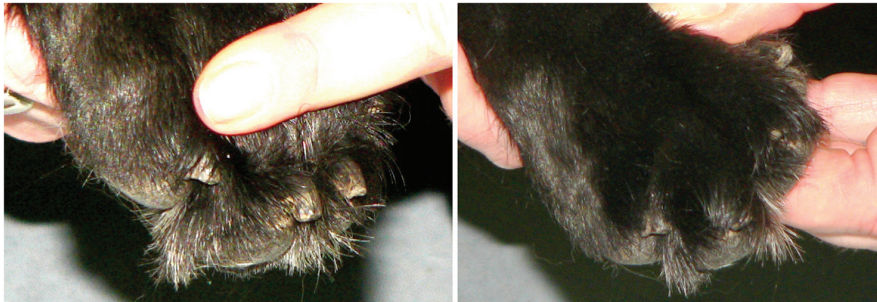


Figure 3. Nails of the front feet after 3 months of the elimination diet

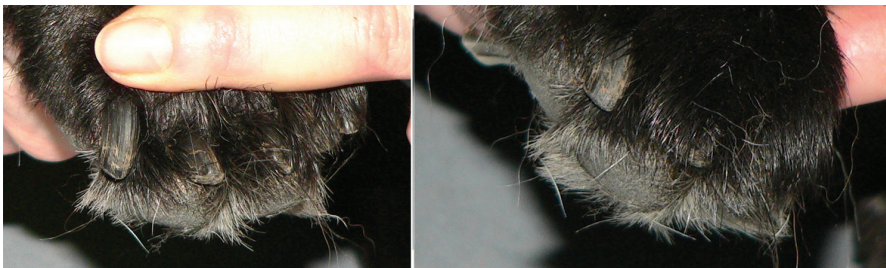


Figure 4. Nails of the back feet after 3 months of the elimination diet

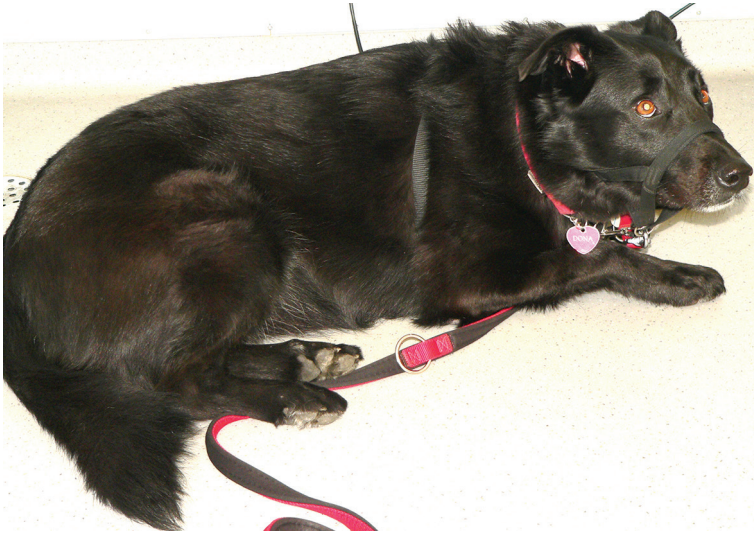


Figure 5. Dog after 9 months of ASIT, with tailored hypoallergenic diet supported by vitamin-E

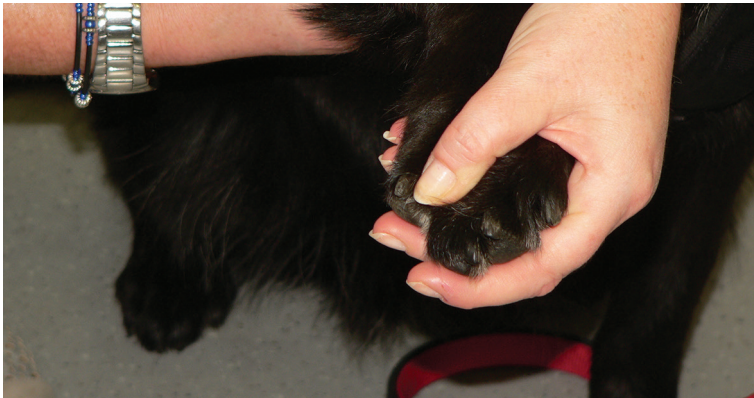

Figure 6. Nails of the front feet after 9 months of ASIT, with tailored hypoallergenic diet supported by vitamin-E

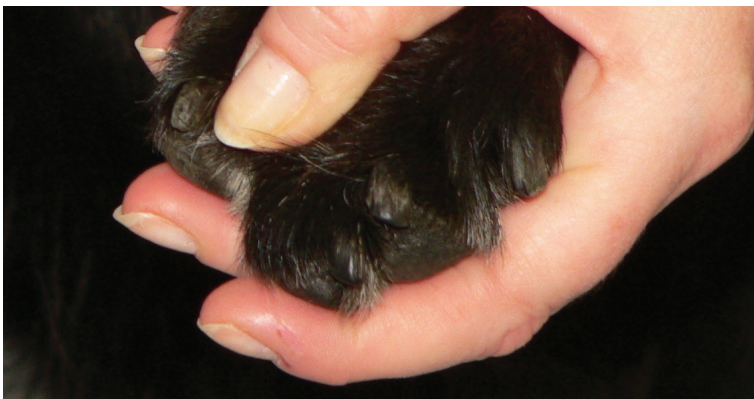

Figure 7. Nails of the back feet after 9 months of ASIT, with tailored hypoallergenic diet supported by vitamin-E

DISCUSSION

The female dog was presented with generalized onychodystrophy together with symptoms of food hypersensitivity (mucous in the stool accompanied with skin changes) and canine atopic dermatitis (CAD; seasonal case, sneezing, eye discharge, and skin changes). The most evident, and therefore, the main problem for the owner was claw disease. Etiologic causes of claw disease are reported to be quite variable. The list of differential diagnoses is long. CAD and food hypersensitivity are listed amongst differentials (Warren, 2013a). About 30% of allergic dogs express combined hypersensitivity to food allergens and simultaneously, environmental allergens (Miller et al., 2013).

Diagnosis of CAD relies on disease history, symptoms and by ruling out conditions that can mimic the disease. Initial symptoms are usually noticed within 6 months to 3 years of age. In our case, the first symptoms were noticed quite late, at 6 years of age. It is possible the owner had not noticed mild symptoms (like groin and ear erythema) when the bitch was younger, if they were present. Another possibility is that the bitch expressed her first symptoms before 3 years of age when it was in the possession of another owner.

Differential diagnoses that should be addressed in CAD involve parasitic and infectious skin diseases (Olivry et al, 2010). In our case, spot-on insecticides were used on a regular basis. *Staphylococcus pseudintermedius*, isolated by bacterial culture in our case, is a resident on dogs' skin and is involved in more than 90% of bacterial skin infections. In the majority of cases, bacterial skin infections in dogs are secondary. They usually respond to antibiotic treatment but are recurrent if the primary cause is not addressed (Miller et al., 2013). That was the case also in our dog, since only transient improvement occurred with antibiotic treatment. The primary cause of recurrent pyoderma in our dog was allergic disease; hypothyroidism as the second most common cause of pyoderma was excluded.

Diagnostic workup in food hypersensitivity should include elimination diet followed by challenge with different foods. Elimination diet should be fed for at least 8-10 weeks and is best constituted of one novel protein and one novel carbohydrate source. Commercial dry foods in our case were replaced with home cooked, individually tailored elimination diet. Home prepared hypoallergenic diets are preferred over the commercial diets due to their lower price and also their effects. Commercial hypoallergenic diets can be less effective due to frequent contamination of dry foods by storage mites (Brazis et al., 2008) and the inclusion of additives to which dogs can be sensitized (Loeffler et al., 2006; Olivry & Bizikova, 2010). Sensitization to the storage mite *Lepidoglyphus destructor* was proven by intradermal sensitivity testing in our bitch. Dry food avoidance is advised in such a case (Miller et al., 2013). After a food challenge with dairy products and fruits, food hypersensitivity in our bitch was proved by relapse of her otitis externa.

Diet trial has occasionally been prescribed as a part of a management of claw disease in dogs. In Mueller's study on 24 dogs, presented exclusively with onychodystrophy, partial or complete resolution of clinical signs after elimination diets was shown in four of them (Mueller, 2000). In another study, symptoms improved in 12 onychodystrophic dogs that were fed Eukanuba Veterinary Diets (EVD) Dermatitis® exclusively for 6 months. There was no evidence of better improvement whether cyclosporine or fish oil were added to the diet (Ziener & Nødtvedt, 2014). In that study, vitamin E as a component of fish oil was added to the diet together with omega-3 fatty acids (10 mg of vitamin E per dog daily) (Ziener & Nødtvedt, 2014). This dosage of vitamin E was rather low, since oral doses suggested for dogs are 1.6-8.3 mg/kg daily (Ramsey, 2008). The author of the present article believes that vitamin E supplemented at higher dosages could improve the outcome of CAD. Plevnik Kapun et al. (2013; 2014) proved the beneficial influence of vitamin E supplementation in CAD. Plasma vitamin E concentrations in dogs with moderate atopic dermatitis were shown to be significantly lower than in healthy controls and significantly lower scores of CADESI-03 were found in atopic dogs treated with vitamin E compared to atopic dogs in a placebo group (Plevnik Kapun et al., 2013; Plevnik Kapun et al; 2014). In the current study, Vitamin E at the dose of 8.1 IU/kg b.m. once daily was, therefore, added to the bitch's diet at the time of the third documented seasonal outbreak of clinical symptoms in 2017.

Intradermal skin test (Artuvetrin, Netherlands) has been used to detect allergens to be included in ASIT. ASIT is the practice of administering gradually increasing quantities of an allergen extract to an allergic subject to ameliorate the symptoms associated with subsequent exposure to the causative allergen (WHO definition) (Bousquet et al., 1998). Desensitization (a synonym for ASIT) has been used in dogs since the mid-20th century, and response to ASIT can be expected in the first year of therapy in about 50-80% of treated dogs. This type of therapy appears effective and safe to reduce signs of CAD. It should therefore be considered in any dog where a diagnosis of CAD has been determined (Olivry et al., 2010).

The growth cycle of dog nails is long (they grow on average 1.9 mm per week), and therefore, 6 to 8 months of treatment is necessary to correct any abnormality (Warren, 2013b). Different studies have used 4- to 6-month-long follow-up periods (Auxilia et al., 2001; Ziener & Nødtvedt, 2014). The follow-up in our case (15 months) seems to have been long enough. Although complete remission in our case has not been achieved, the owner considered the absence of painful relapses of onychomadesis as a good response to the treatment. Despite the claws still showing some signs of onychodystrophy (Figures 6-7), the quality of the female dog's life, according to its owner's opinion, has markedly improved.

CONCLUSION

Although the female dog was presented with erythematous skin of the ear canals and groin, accompanied by some other symptoms (sneezing, eye discharge and

mucoid stool), claw disease was the most prominent. It was actually the only problem considered as important by the owner. An elimination diet and intradermal sensitivity testing, followed by a challenge diet and ASIT, appear to be worthwhile diagnostic tests and therapeutic measures for patients with claw disease.

Competing interests

The authors declare that they have no competing interests.

REFERENCES

- Auxilia S. T., Hill P. B., Thoday K. L. 2001. Canine symmetrical lupoid onychodystrophy: a retrospective study with particular reference to management. *Journal of Small Animal Practice*, 42:82-87. <https://doi.org/10.1111/j.1748-5827.2001.tb01998.x>
- Bousquet J., Lockey R., Malling H. J., et al. 1998. Allergen immunotherapy: therapeutic vaccines for allergic diseases. World Health Organization. American Academy of Allergy, Asthma and Immunology. *Annals of Allergy, Asthma and Immunology*, 81:401-405.
- Brazis P., Serra M., Sellés A., Dethioux F., Biourge V., Puigdemont A. 2008. Evaluation of storage mite contamination of commercial dry dog food. *Veterinary Dermatology*, 19:209-214. <https://doi.org/10.1111/j.1365-3164.2008.00676.x>
- Loeffler A., Soares-Magalhaes R., Bond R., Lloyd D. H. 2006. A retrospective analysis of case series using home-prepared and chicken hydrolysate diets in the diagnosis of adverse food reactions in 181 pruritic dogs. *Veterinary Dermatology*, 17:273-279. <https://doi.org/10.1111/j.1365-3164.2006.00522.x>
- Mueller R. S. 2000. Diagnosis of canine claw disease – a prospective study of 24 dogs. *Veterinary Dermatology*, 11(2):133-141. <https://doi.org/10.1046/j.1365-3164.2000.00174.x>
- Miller W. H., Griffin C. E., Campbell K. L. 2013. *Muller & Kirk's Small animal dermatology*. 7th ed. W.B. Saunders Company, St. Louis, Missouri.
- Olivry T., Bizikova P. 2010. A systematic review of the evidence of reduced allergenicity and clinical benefit of food hydrolysates in dogs with cutaneous adverse food reactions. *Veterinary Dermatology*, 21:32-41. <https://doi.org/10.1111/j.1365-3164.2009.00761.x>
- Plevnik Kapun A., Salobir J., Levart A., Tavcar Kalcher G., Nemeč Svete A., Kotnik T. 2013. Plasma and skin vitamin E concentrations in canine atopic dermatitis. *Veterinary Quarterly*. <https://doi.org/10.1080/01652176.2012.758395>.
- Plevnik Kapun A., Salobir J., Levart A., Tavcar Kalcher G., Nemeč Svete A., Kotnik T. 2014. Vitamin E supplementation in canine atopic dermatitis: improvement of clinical signs and effects on oxidative stress markers. *Veterinary Record*, 175(22):560. Epub 2014 Sep 9. <https://doi.org/10.1136/vr.102547>
- Ramsey I (ed.). 2008. *BSAVA Small animal formulary*. Replika Press, 6th ed.
- Ziener M. L., Nødtvedt A. 2014. A treatment study of canine symmetrical onychomadesis (symmetrical lupoid onychodystrophy) comparing fish oil and cyclosporine supplementation in addition to a diet rich in omega-3 fatty acids. *Acta Veterinaria Scandinavica*, 56:66. <http://www.actavetscand.com/content/56/1/66>
- Warren S. 2013a. Claw disease in dogs: Part 1 – anatomy and diagnostic approach. *Companion Animal*, 18(4):165-170.
- Warren S. 2013b. Claw disease in dogs: part 2 – diagnosis and management of specific claw diseases. *Companion Animal*, 18(5):226-231.

ALERGIJSKA BOLEST KOD PASA PRAĆENA GENERALIZOVANOM ONIHODISTROFIJOM

KOTNIK Tina

Kratak sadržaj

Alergija na hranu i atopični dermatitis su dve najčešće alergijske bolesti kod pasa. Alergija na hranu je tipično nesezonska alergijska reakcija tipa I, III i IV. Najčešći alergeni u hrani jesu glikoproteini. Atopični dermatitis kod pasa je genetski predisponirana upalna bolest kože sa karakterističnim kliničkim promenama koje svrbe i izazvane su antitelima tipa IgE koja se stvaraju u borbi protiv alergena iz okoline. Nezavisno na koje alergene su psi osetljivi, klinički simptomi kod akutnih slučajeva su svrab sa eritemom kože oko usana, pazuha, ingvinalne i perianalne regije ili šapa, kao i upala spoljašnjeg ušnog kanala. Kod hroničnih slučajeva na koži možemo naći posledice autotraumatizacije i sekundarne bakterijske ili gljivične infekcije u obliku ekskoriacija, lihenifikacije i hiperpigmentacije. Alergijska bolest može imati jak uticaj na kvalitet života pasa kao i na kvalitet života vlasnika.

Predstavljen je slučaj kuje, mešanca, sa jako izraženom generalizovanom onihodistrofijom, praćenom blagim eritemom kože i blagom upalom spoljašnjeg ušnog kanala. Dobar rezultat je postignut eliminacionom dijetom i specifičnom antigenskom imunoterapijom.

Ključne reči: onihodistrofija, CAD, alergija na hranu, pas, ASIT